

PLANNING & MANAGEMENT

IMPULSVORTRAG INTRAOPERATIVE VENOGRAPHIE - AUSREICHEND?

DR. ENIDA REXHA

ASKLEPIOS KLINIK ST. GEORG, HAMBURG

E.REXHA@ASKLEPIOS.COM

TLE COMMUNITY & FRIENDS

The future belongs to those who prepare for it today!

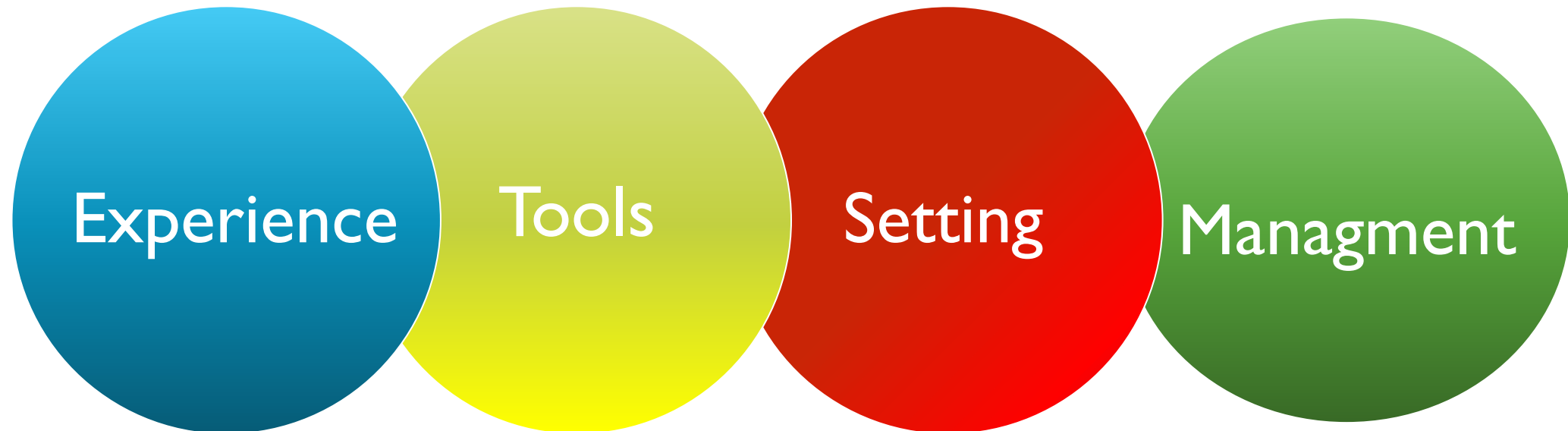
WISSENSCHAFTLICHE LEITUNG:

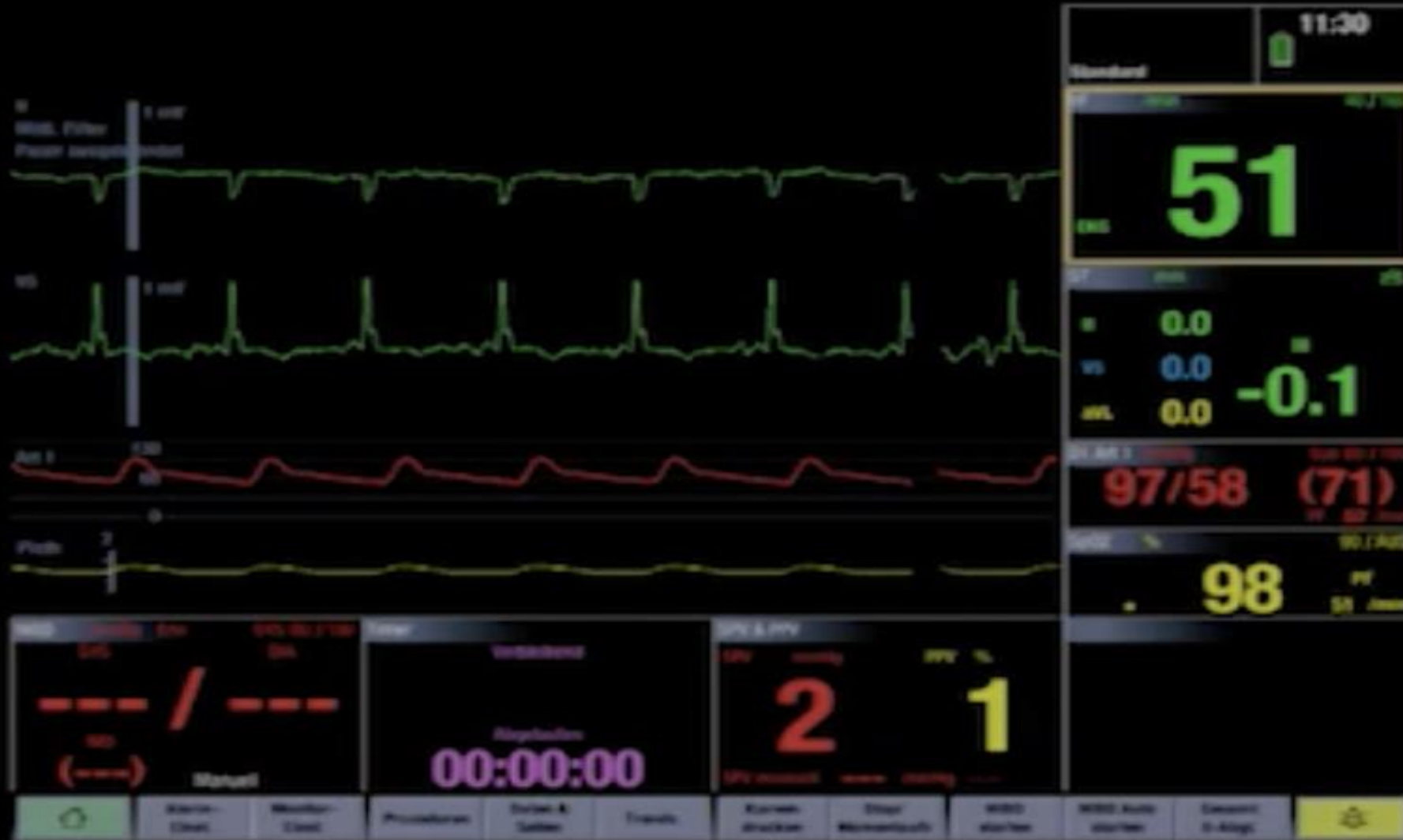
PD Dr. med. Samer Hakmi, Asklepios Klinik St. Georg
Radisson Blu, Congressplatz 2, 20355 Hamburg

INTRODUCTION


Successful TLE Procedure?

INTRODUCTION






TOOLS



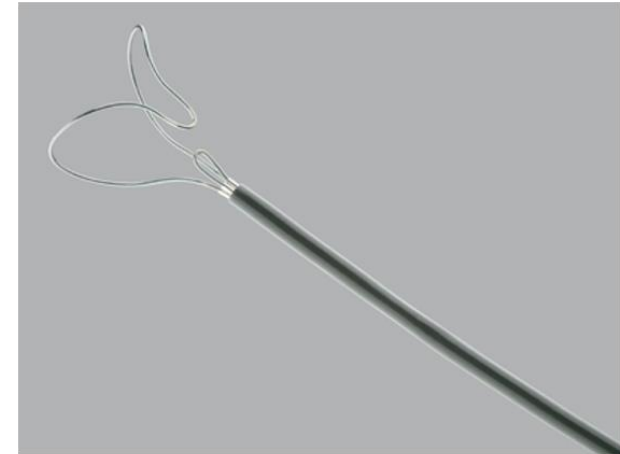
TOOLS



Mechanical dilator sheath

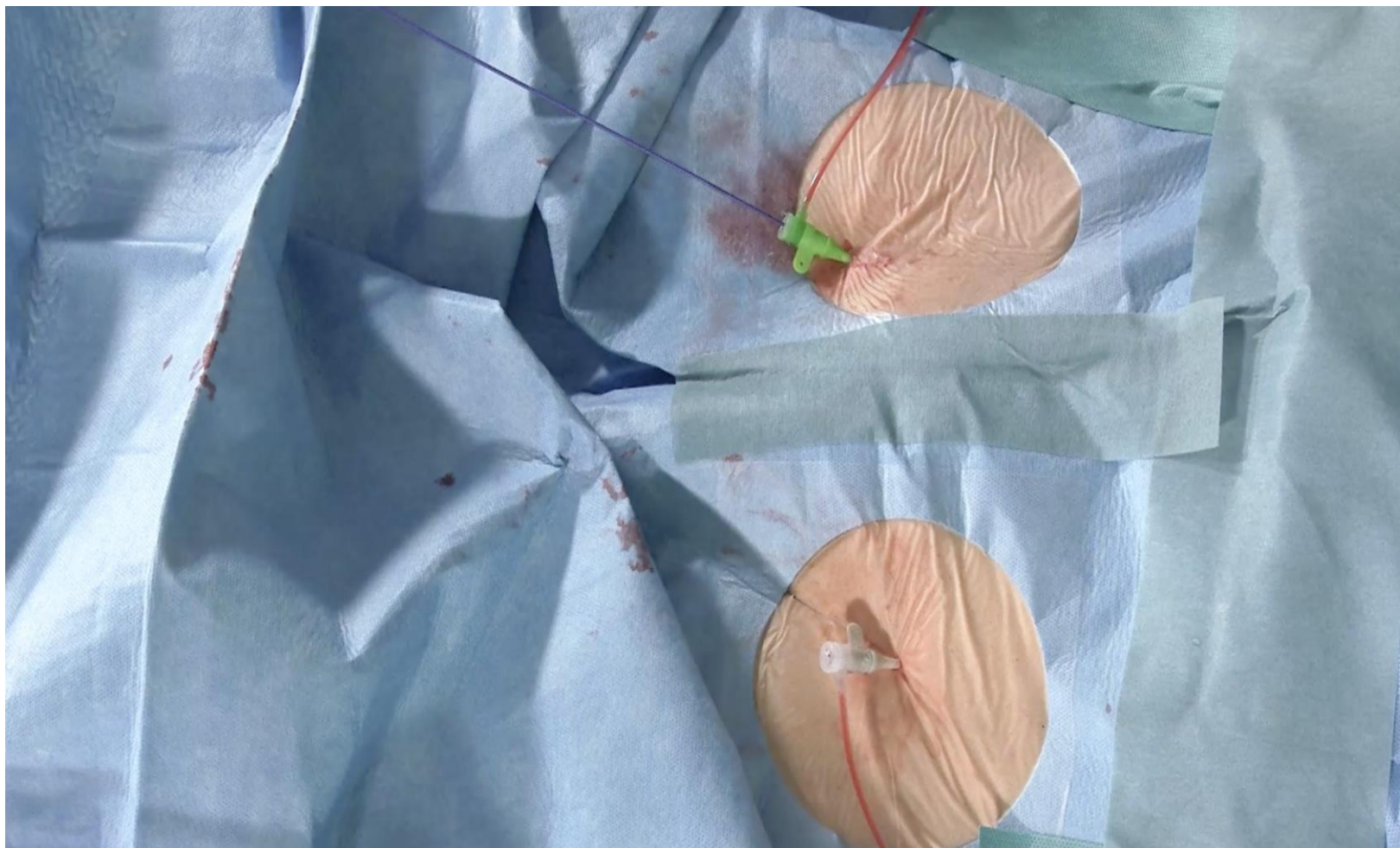


Excimer laser sheath

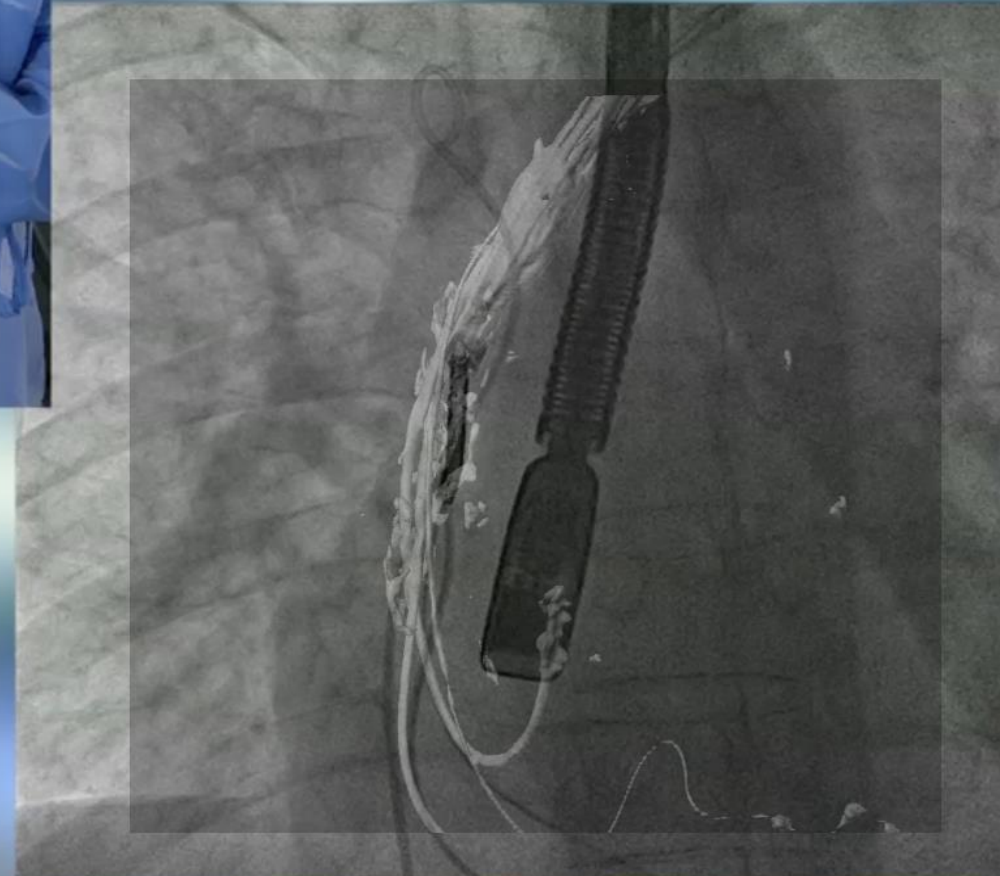
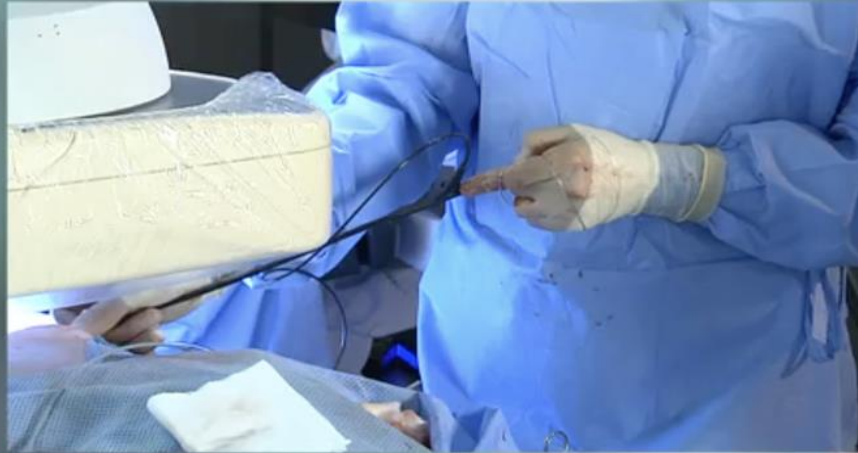

Needle's eye snare

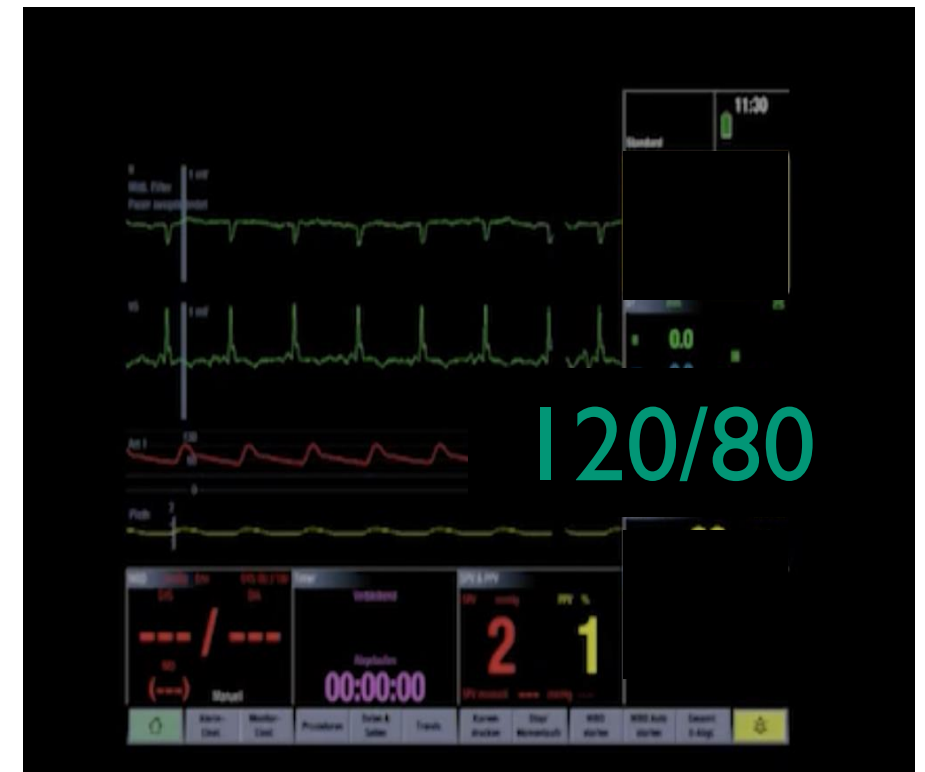
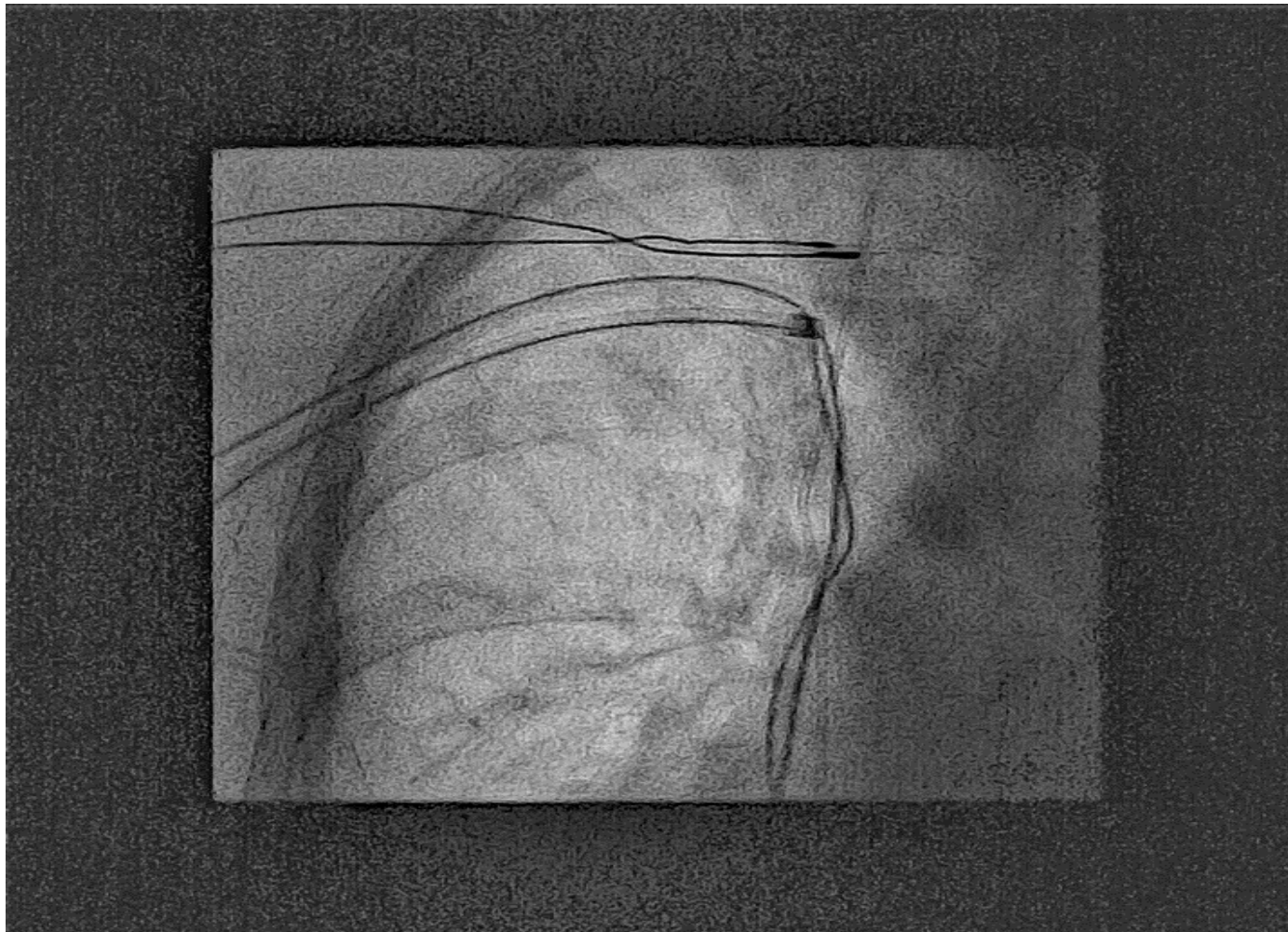
SECOND ACCESS



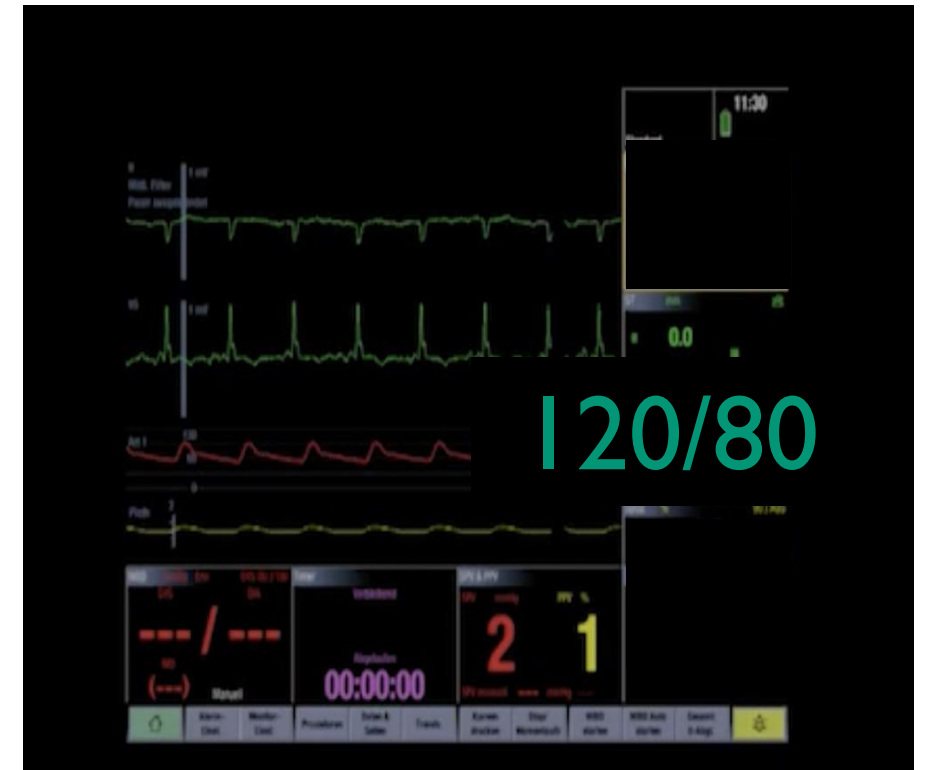
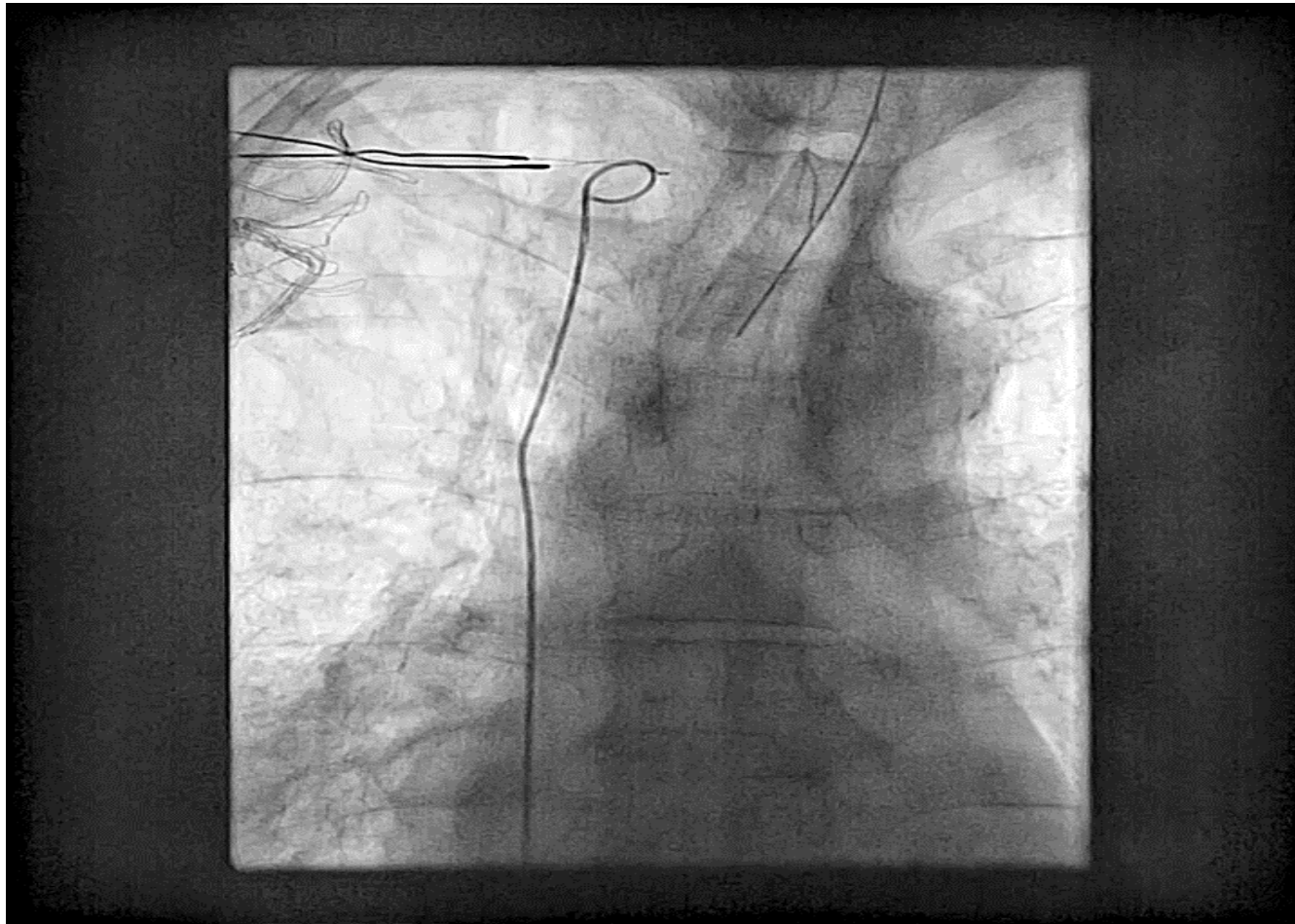
AGGRESSIVE ADHESIONS



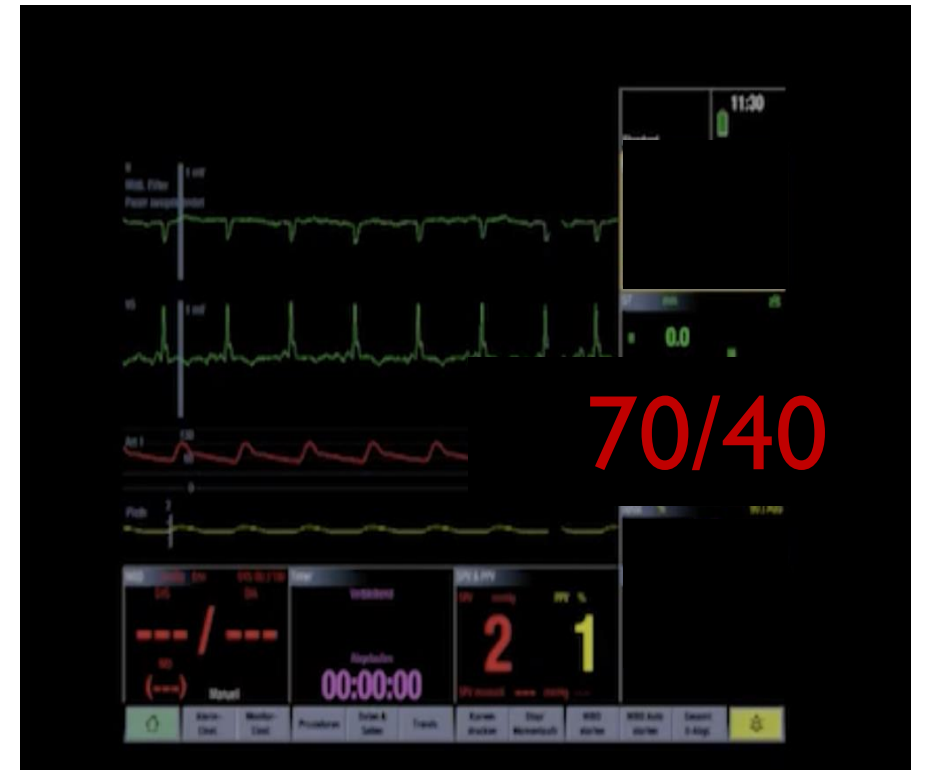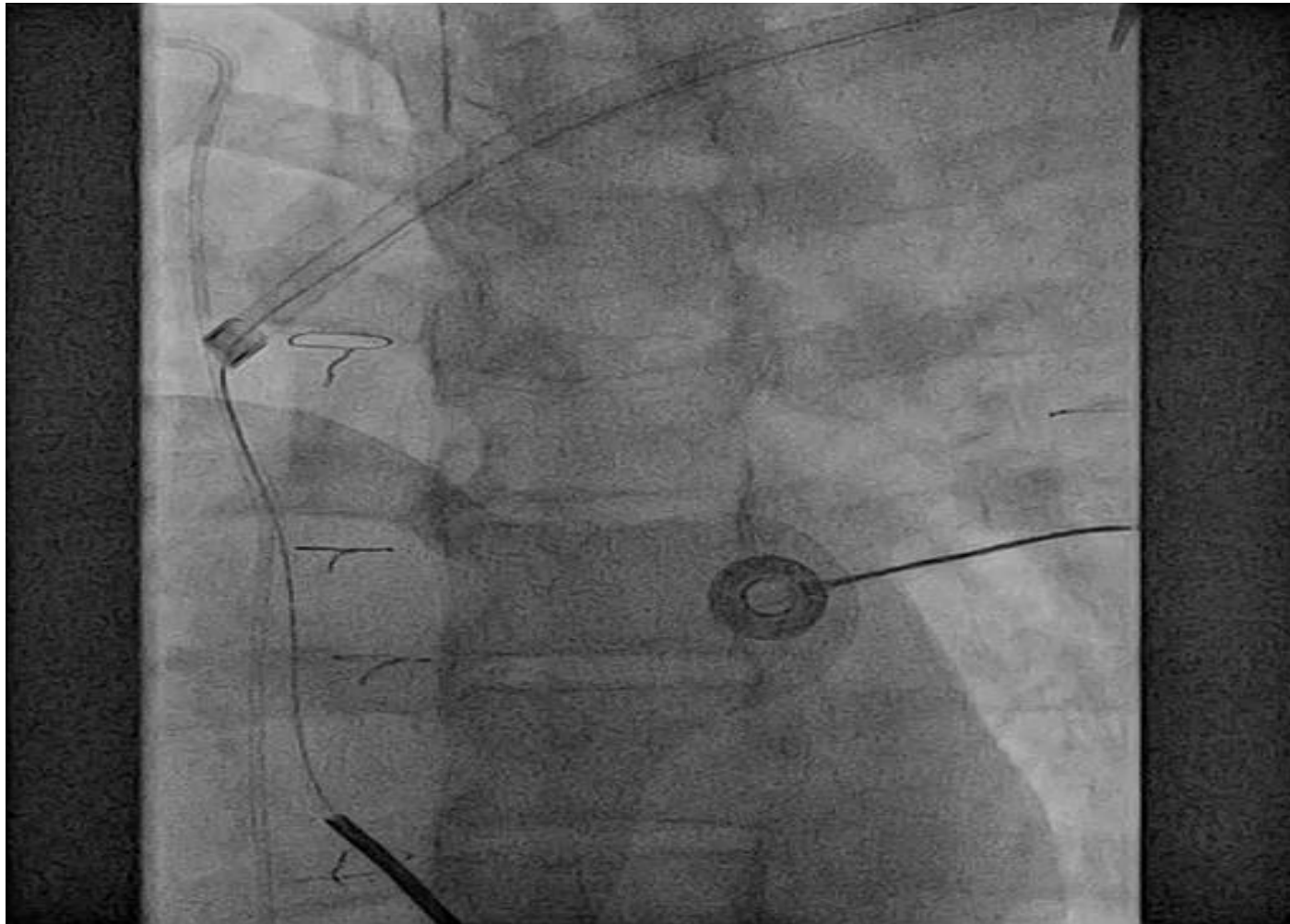
DATA / CLINICAL PROBLEM I



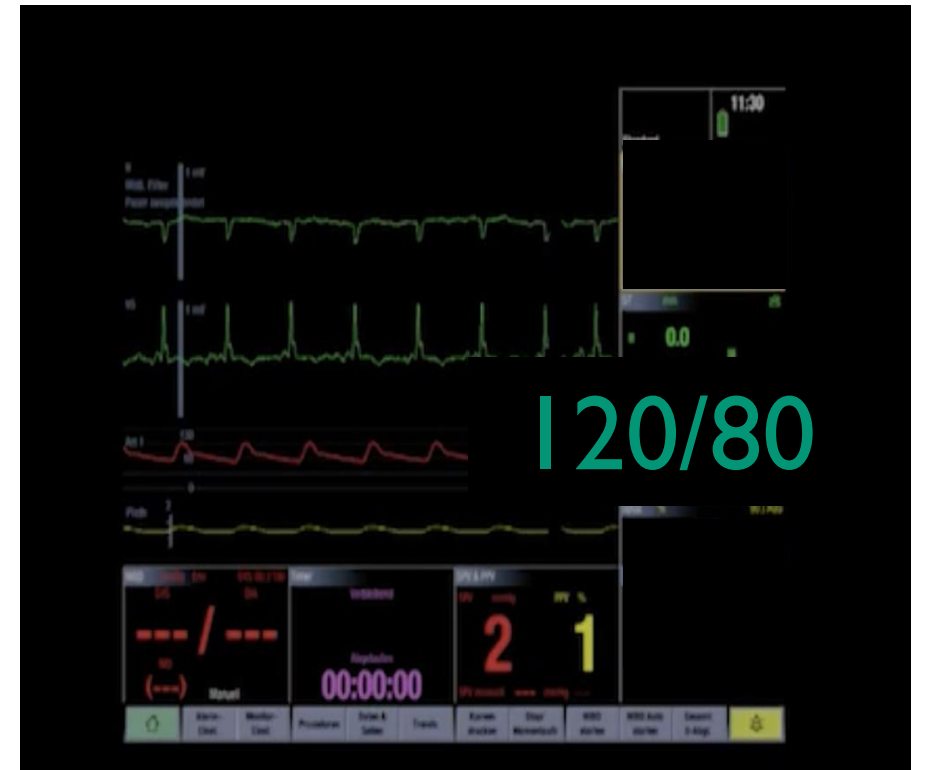
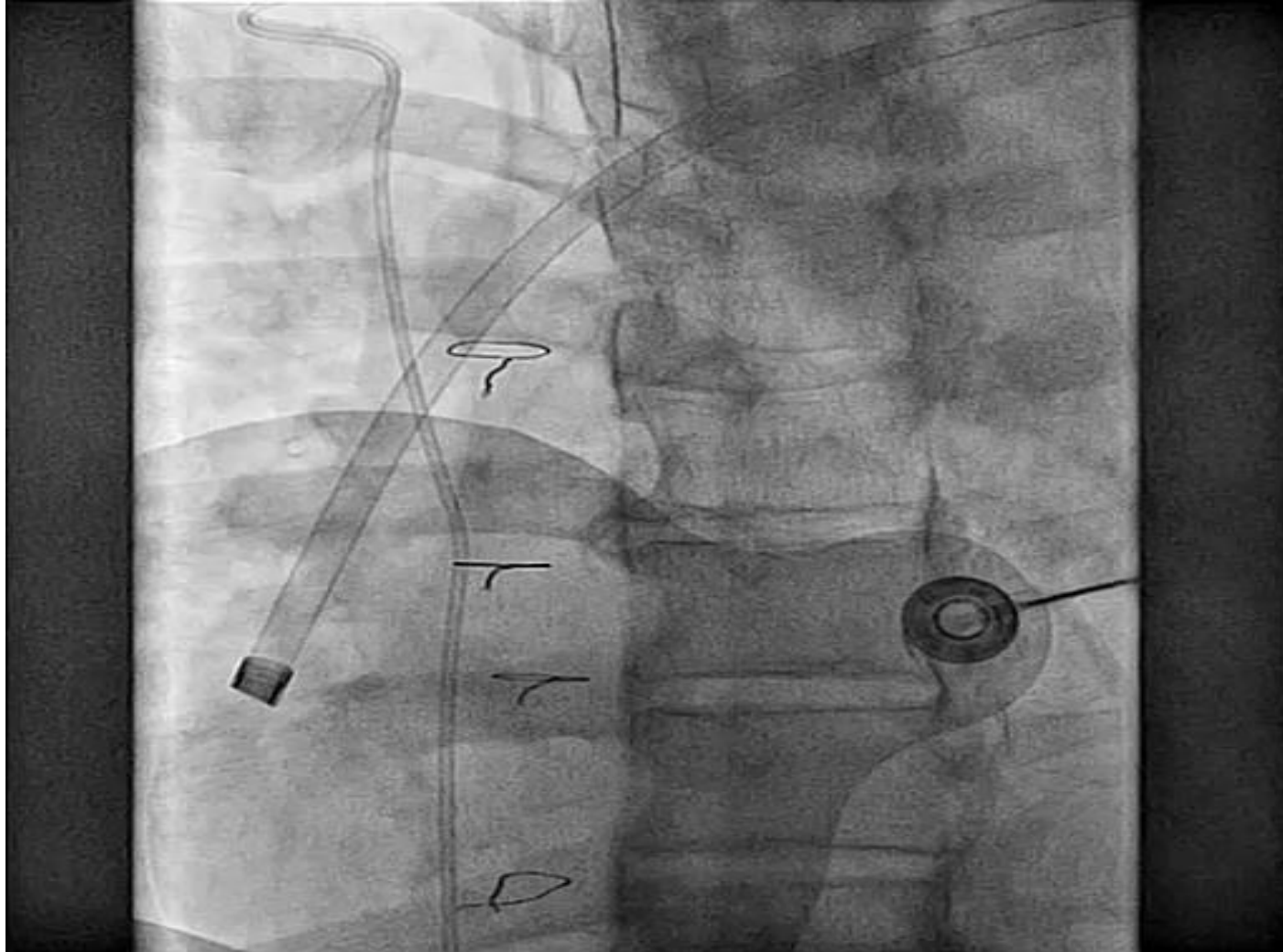
EXPERIENCE I



DATA / CLINICAL PROBLEM II



EXPERIENCE II



DISCUSSION

Clinical utility of routine use of continuous transesophageal echocardiography monitoring during transvenous lead extraction procedure

Severe PE: 1 out 168 Patients

Severe PE: Laceration of the SVC

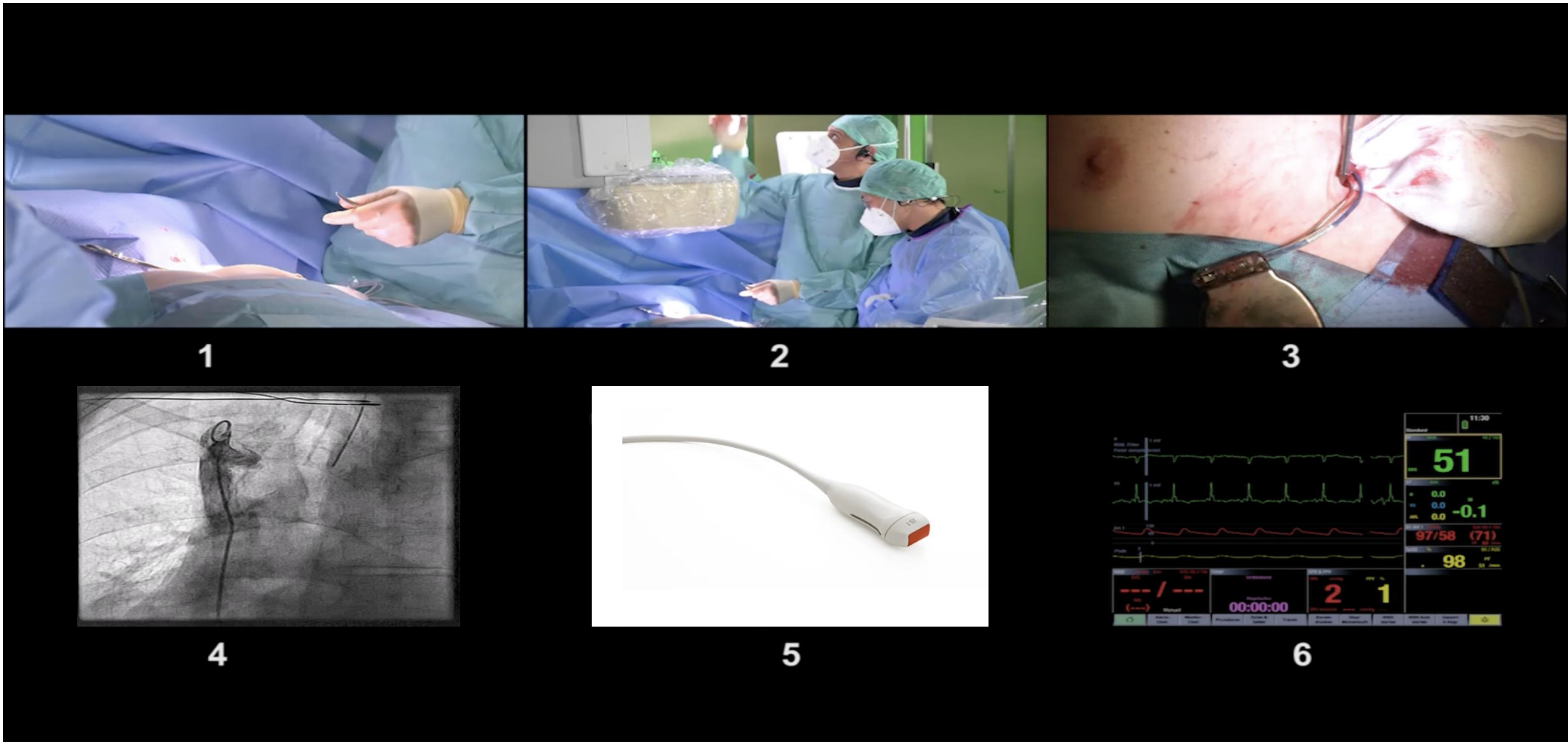


ASKLEPIOS KLINIK
ST. GEORG

Data for complications in patients who underwent TLE in our clinic.

07/2019-09/2023	130 Patients
Severe PE	1 (0.8%)
Total Nr. of complications	2 (1.5%)

DISCUSSION: OUR SETTINGS TODAY



KEY QUESTION

Auf welche Bildmodalität würden sie bei TLE am ehesten verzichten?

- a. Transösophageale Echokardiographie
- b. Fluoroskopie