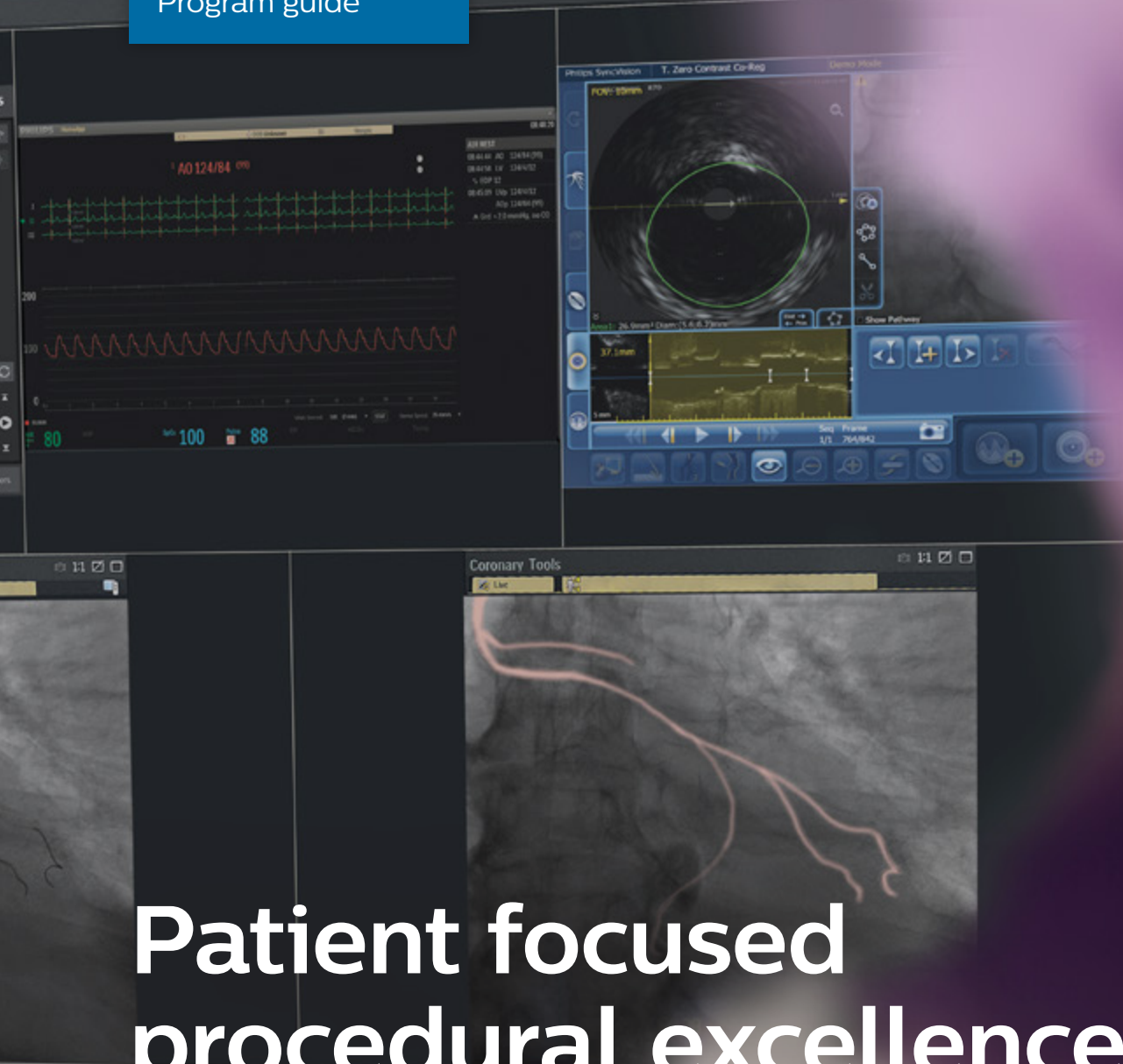


PHILIPS

Ultra-low
contrast PCI

Program guide



**Patient focused
procedural excellence**

PHILIPS

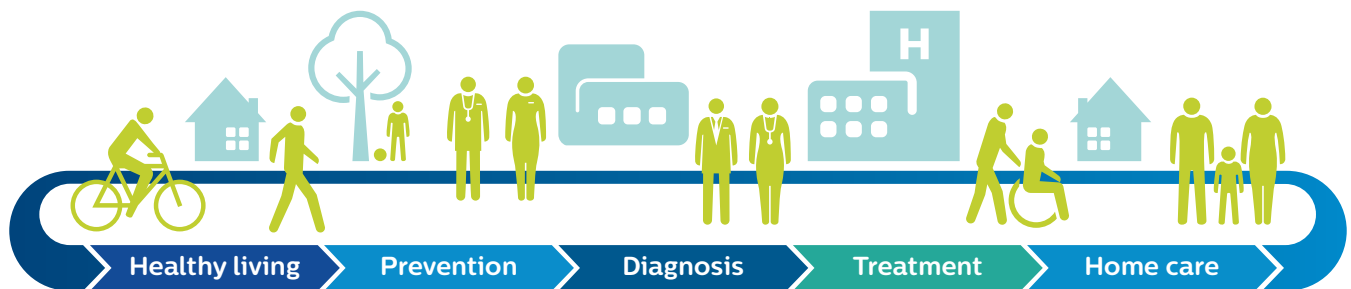Table of contents

| | |
|--|----|
| Philips approach to coronary artery disease | 2 |
| <hr/> | |
| The problem to solve – reducing the incidence of AKI | 4 |
| <hr/> | |
| Consequences of AKI | 5 |
| <hr/> | |
| Renalism in the patient pathway | 6 |
| <hr/> | |
| Clinical techniques for contrast reduction | 7 |
| <hr/> | |
| Technology to support contrast reduction | 14 |
| <hr/> | |
| The cath lab team | 15 |
| <hr/> | |

Philips approach to coronary artery disease

At Philips Image Guided Therapy, we have played a pioneering role in image-guided minimally invasive therapy for cardiovascular disease since the inception of the field back in the 1950s, thanks to our expertise in X-ray imaging systems. We aim to both improve existing procedures and introduce new procedures so that more patients can benefit from image-guided therapy. We also develop new business models to cater for new care settings, such as ambulatory surgery centers and office-based labs and drive improved lab performance.

Philips is about driving clinical efficiency. Driving the highest level of clinical outcomes while minimizing complications. And by integrating our systems and platforms, we deliver diagnostic confidence and operational efficiency.



We see healthcare as a connected whole. Helping people to live healthy and prevent disease. Giving physicians the tools to make precision diagnosis and deliver personalized treatment, aiding the patient's recovery at home in the community and supporting a seamless flow of data.

Challenges in CAD

As the prevalence of coronary artery disease (CAD) grows, interventional cardiologists are feeling the strain. With an ever-increasing caseload and strained resources, delivering confident diagnoses and efficient, cost-effective, high-quality care presents significant challenges. The key to unlocking the power of diagnostic confidence, optimal outcomes, and time savings is...clinical efficiency.



40% of patients sent to the cath lab do not require a stent.¹



Non-invasive diagnostic exams with suboptimal images, result in costly retesting.²



Difficulty in getting immediate access to tools, images and reporting for multimodality diagnosis.³

The problem to solve – reducing the incidence of acute kidney injury

Acute kidney injury (AKI) is a serious complication of angiographic procedures resulting from the administration of contrast medium.

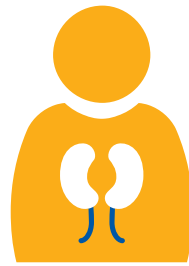
Most cardiac patients fall under the high-risk category for AKI. Heart failure, ST-elevation myocardial infarction (STEMI), cardiogenic shock, chronic kidney disease (CKD), age, and diabetes contribute to the higher incidence of kidney injury.⁴

Contrast induced nephropathy (CIN) is one of the major causes of hospital-acquired AKI.⁵

- >4 million hospitalizations reported each year.
- Patients who undergo coronary angiography are at highest risk for CIN.
- CIN is considered the 3rd most common cause of hospital-acquired renal dysfunction.



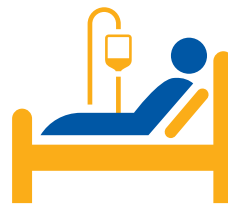AKI affects 1 in 5 hospitalized patients⁶



Inpatient mortality for AKI patients is 20–25%, 50% for those on dialysis⁷



AKI was associated with an increase in hospitalization cost of \$9,448⁸



AKI was associated with an increase length of stay of 3.6 days⁸

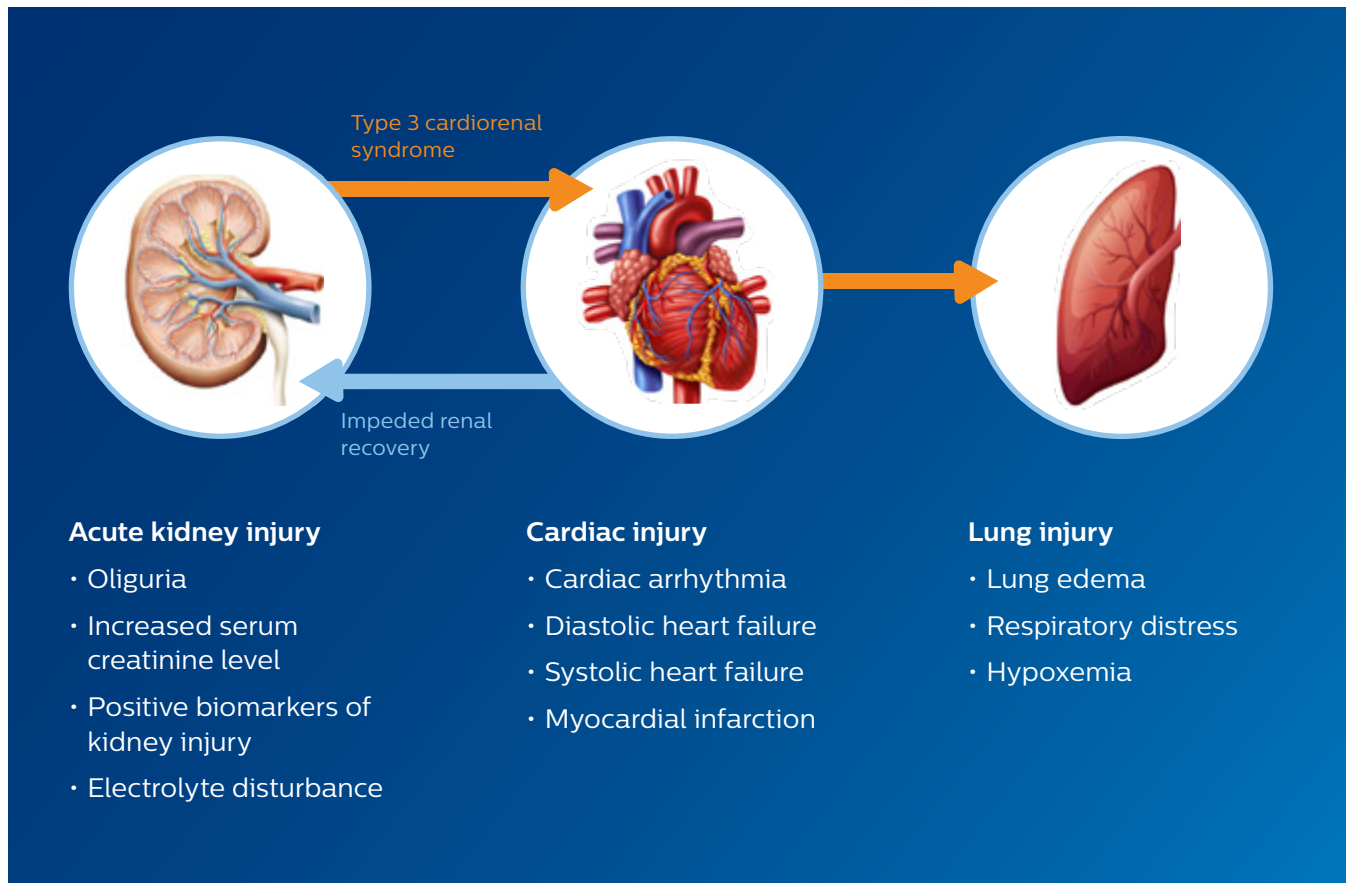
The American College of Cardiology’s National Cardiovascular Data Registry (NCDR) CathPCI registry has a low threshold (rise in serum creatinine of 0.3 mg/dL) for AKI and encourages quality improvements.

Contrast medium has a “two-hit” model of direct contrast-induced renal tubular epithelial cell toxicity and vasoconstriction within the renal arteries that can last up to several hours, which results in the kidneys becoming ischemic and a decreased glomerular filtration rate (GFR) that causes a rise in creatinine. This complication adds to the patient’s length of stay and cost accrual to the hospital.

Consequences of acute kidney injury

Mortality from AKI is high, it is associated with an increased risk of death, both short-term and long-term cardiovascular complications, and up to 60% of patients with severe AKI who are admitted to an ICU, die from the disorder.⁹

A 2017 meta-analysis of 25 studies involving a total of 254,408 patients, including 55,150 with acute kidney injury, showed that AKI was associated with an 86% increase in the risk of death from cardiovascular causes during a median follow-up of 1.4 years.¹⁰

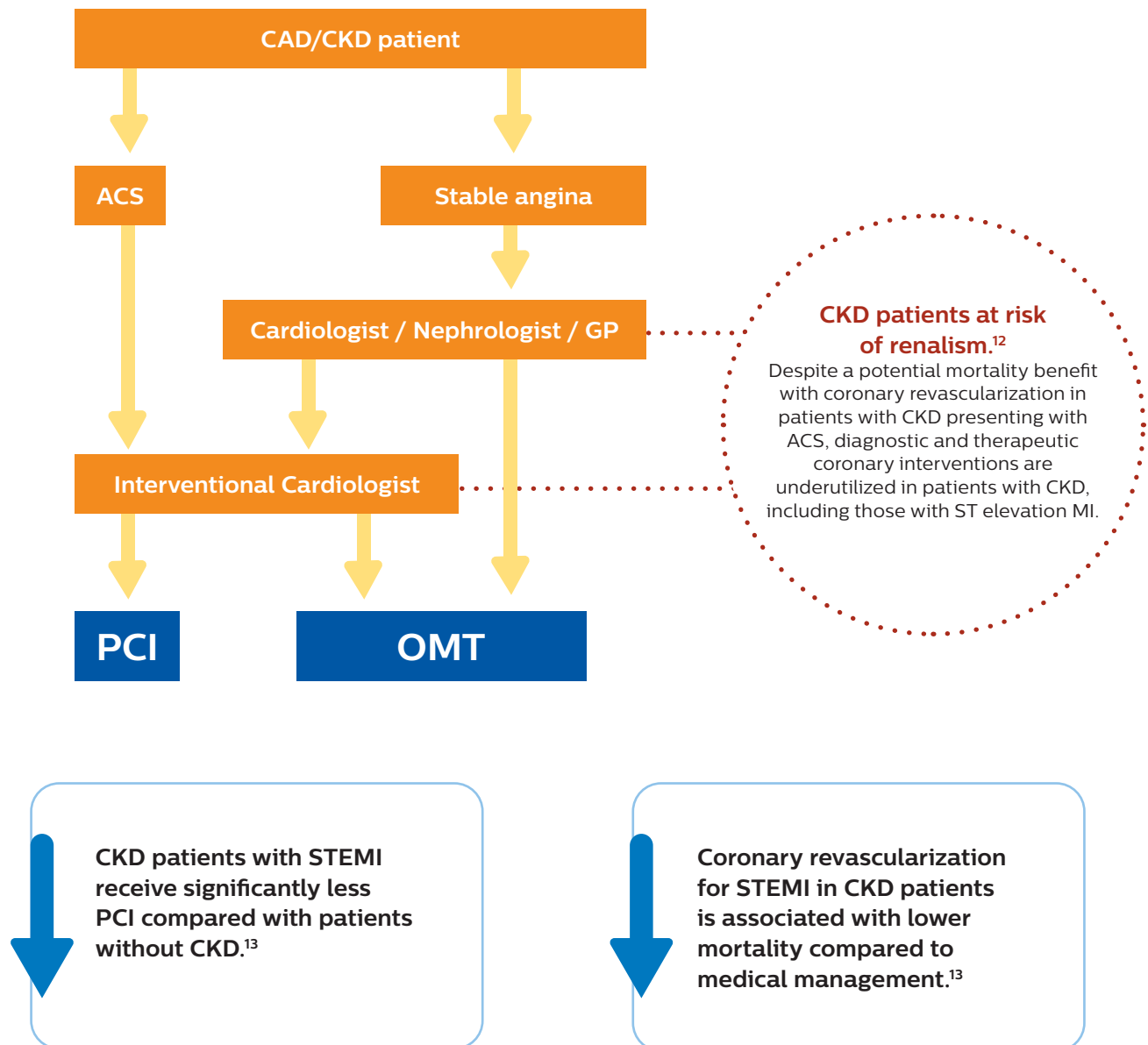


AKI has been shown to promote cardiac injury and dysfunction, defined as type 3 cardiorenal syndrome. Heart failure, in turn, can impede renal recovery. Lung injury and hypoxemia after acute kidney injury can arise both from increased capillary permeability and from increased hydrostatic capillary pressure due to heart failure.

Renalism in the patient pathway

“Renalism”: Inappropriately low rates of coronary angiography in elderly individuals with renal insufficiency¹¹

There is a significant decrease in utilization of coronary angiography among patients with CKD, possibly because of an aversion to the risk of CIN.



*Chart represents a simplification of the true patient pathway

Clinical techniques for contrast reduction



Ultra-low contrast coronary angiography and zero-contrast percutaneous coronary intervention for prevention of contrast-induced nephropathy: **step-by-step approach and review**¹⁴

Prof. Dariusz Dudek, President EAPCI ESC. Jagiellonian University, Krakow, Poland

1

Catheter engagement without contrast administration:

- Radial arteries should be saved for arteriovenous fistula in case of chronic hemodialysis. Detailed analysis of the calcium distribution may help to identify the arteries and guide the catheter engagement.
 - High frame rate acquisition (i.e., 30 frames) exposes calcified changes and greatly facilitates identification of the vessels.
 - To confirm the proper engagement, inject 10–20 ml of saline through the catheter and observe temporal changes in the electrocardiogram.¹⁵ If the catheter is properly inserted, the saline injection induces the T-wave inversion or increases its amplitude along with ST-segment depression or elevation.
 - To confirm the appropriate catheter position, introduce a coronary guidewire into the artery, (i.e. if the guidewire follows the anatomy of the coronary artery, then this is the confirmation of proper engagement).
-

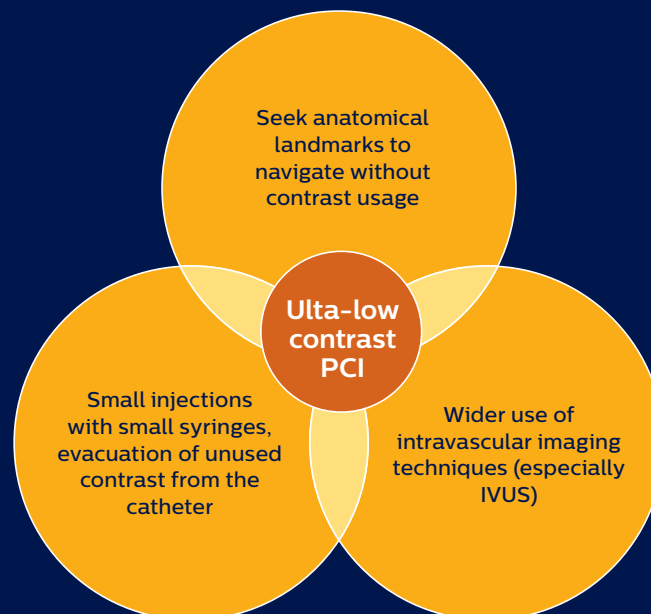
2

Ultra-low contrast coronary angiography

- A nonionic, iso-osmolar contrast agent is preferred, and its pre-specified maximum volume should be based on the ratio of contrast volume (CV) per estimated glomerular filtration rate (eGFR): when the ratio (i.e., CV/eGFR) is less than 1, the risk of CIN is significantly reduced (e.g., if the patient's eGFR equals 20 ml/min/1.73 m², the contrast volume should not exceed 20 ml).¹⁶⁻¹⁸
- The low-dose contrast injections should be performed through small diameter catheters (i.e., 5–6 Fr) without side-holes and with small syringes (e.g., 3 or 5 ml) to enable fast and easy administration (dye “puffing” should be avoided).
- Usually, as the arterial tree appears sequentially as the low-contrast volume flows from its proximal to distal portion, the acquisition time should be appropriately adjusted, with a high frame rate being preferred (i.e., 30 frames/s): that significantly improves vessel visualization.
- Before any drug administration (e.g., nitroglycerine) or when exchanging catheters, contrast medium must be removed from the catheter to avoid pushing it into the patient.
- Projections: The left coronary artery angiography usually begins from the spider view and then the cranial right anterior oblique projection is acquired; other projections depend on lesions' distribution and visualization. For right coronary angiography, the cranial left anterior oblique projection is usually sufficient. Optionally, acquisition with the right anterior oblique projection may be performed. If more projections are necessary, contrast dilution with saline 2:1 may limit the overall contrast amount.
- The same projections that were employed during the angiography must be used for PCI, and previous angiographic images should be displayed alongside the active fluoroscopy screen as a reference.

Ultra-low contrast coronary intervention

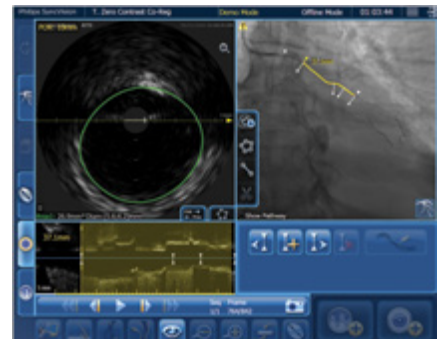
- Workhorse guidewires without hydrophilic-coated tips are preferred to mitigate the risk of vessel perforation. It is useful to create an excessive curve at the tip of the wire so that the tip will form a loop after crossing the stenotic lesion, and by pushing such a “knuckled” wire (without rotating) one may safely insert it even throughout a tortuous vessel.
- Intravascular ultrasound imaging (IVUS), helps to identify the lesion and its length (i.e., “normal-to-normal” distance), reference vessel diameters and landing zones for stent implantation.^{19,20}
- When the position of guidewire is correct, but the IVUS probe cannot cross the stenotic lesion, its location should be recorded with cine angiography and such an image will provide a reference for balloon pre-dilation.
- The first non-diseased segment behind the lesion (or a segment with plaque burden less than 50% in cases with diffuse lesions) constitutes the distal landing zone, and importantly, the corresponding IVUS probe position should be recorded. The same must be done for the proximal landing zone.
- The most helpful landmarks are calcifications within vessels and the chest wall, overlying the ribs, diaphragm, surgical clips (in patients after coronary artery bypass grafting) as well as the catheter position, which all together may assist in proper stent positioning and implantation.²⁰⁻²²
- After stent placement, IVUS imaging ascertains stent expansion and may reveal edge dissection.
- Almost all interventional techniques can be employed during zero-contrast PCI. Particularly, physiological assessment of coronary lesions with pre- and post-PCI measurements of fractional flow reserve (FFR) and coronary flow reserve (CFR) turned out to be very helpful for both procedure guidance and confirmation of physiological improvement after intervention.²⁰
- By holding the workhorse wire in the vessel and with the help of a double lumen microcatheter, one may insert a pressure wire several times and do pull-back measurements with minimal risk of vessel damage. Also, by using a single lumen microcatheter one may safely exchange the operating wire for a pressure wire and vice versa.



4

Techniques for procedure navigation

- With the so-called “marking wire technique” two wires are inserted into the coronary artery through a double Y connector: the operating wire is put in via the main port but the marking wire via the side port of the connector.¹² The marking wire serves as a guide for stent positioning, i.e., its tip is placed at the level of the distal landing zone determined by IVUS and then its position is secured by screwing the connector’s side port and by attaching a torquer. With such a marking wire, one may subsequently determine (by using IVUS) the proximal landing zone and the stent length.
- Another technique that helps in orientation within a coronary artery relies on building a metallic silhouette of the vessel with guidewires.^{20,23} Side branches often provide important landmarks for stent implantation, and by wiring these branches along with the main vessel, one may create a metallic silhouette of the artery [...] such wires also secure side branches from occlusion during PCI.
- Real-time angiographic co-registration of IVUS images is very helpful in such interventions. This technique can be used without contrast injection and allows merging of the probe position on the guidewire with IVUS pictures, i.e., “dry” angiographic co-registration of IVUS.



5

Safety measures

As in any other invasive coronary procedures, it is mandatory to monitor hemodynamics throughout the interventions.

It is advisable to perform ultra-low contrast PCI (ULCPCI) procedures only for large and prognostically or clinically relevant coronary vessels. The risk of complications is probably higher when the target vessel diameter is small. In such circumstances, incorrect wiring of small side branches is very likely, and if unrecognized, may lead to perforation.

Post-PCI echocardiography should be performed to check for pre-existing pericardial effusion and new or enlarging effusion after PCI.

Some other situations may require radio-contrast angiography during zero-contrast PCI, i.e., persistent chest pain, new electrocardiographic changes, hemodynamic compromise, lack of improvement in physiological indices (i.e., FFR, CFR) and new or enlarging pericardial effusion.²⁴

Due to legal issues, it is sensible to document the final PCI result with a single injection of a small contrast volume.

6

Adequate patient's hydration

- Although contrast volume reduction plays a critical role in preventing CIN, adequate patient's hydration remains the cornerstone for this prevention.
- In the POSEIDON trial, left ventricular end-diastolic pressure (LVEDP) guided fluid administration proved to be very effective and a safe way to prevent CIN in patients undergoing cardiac catheterization.²⁵

According to this study, each patient should receive a bolus of saline infusion at 3 ml/kg for 1 h before the procedure [...] then, the fluid rate administration is adjusted in line with LVEDP, i.e.: 5 ml/kg/h for LVEDP lower than 13 mm Hg, 3 ml/kg/h for LVEDP of 13–18 mm Hg, and 1.5 ml/kg/h for LVEDP higher than 18 mm Hg. Such a fluid rate is started at the beginning of the procedure and continued during the procedure and for the next four hours.

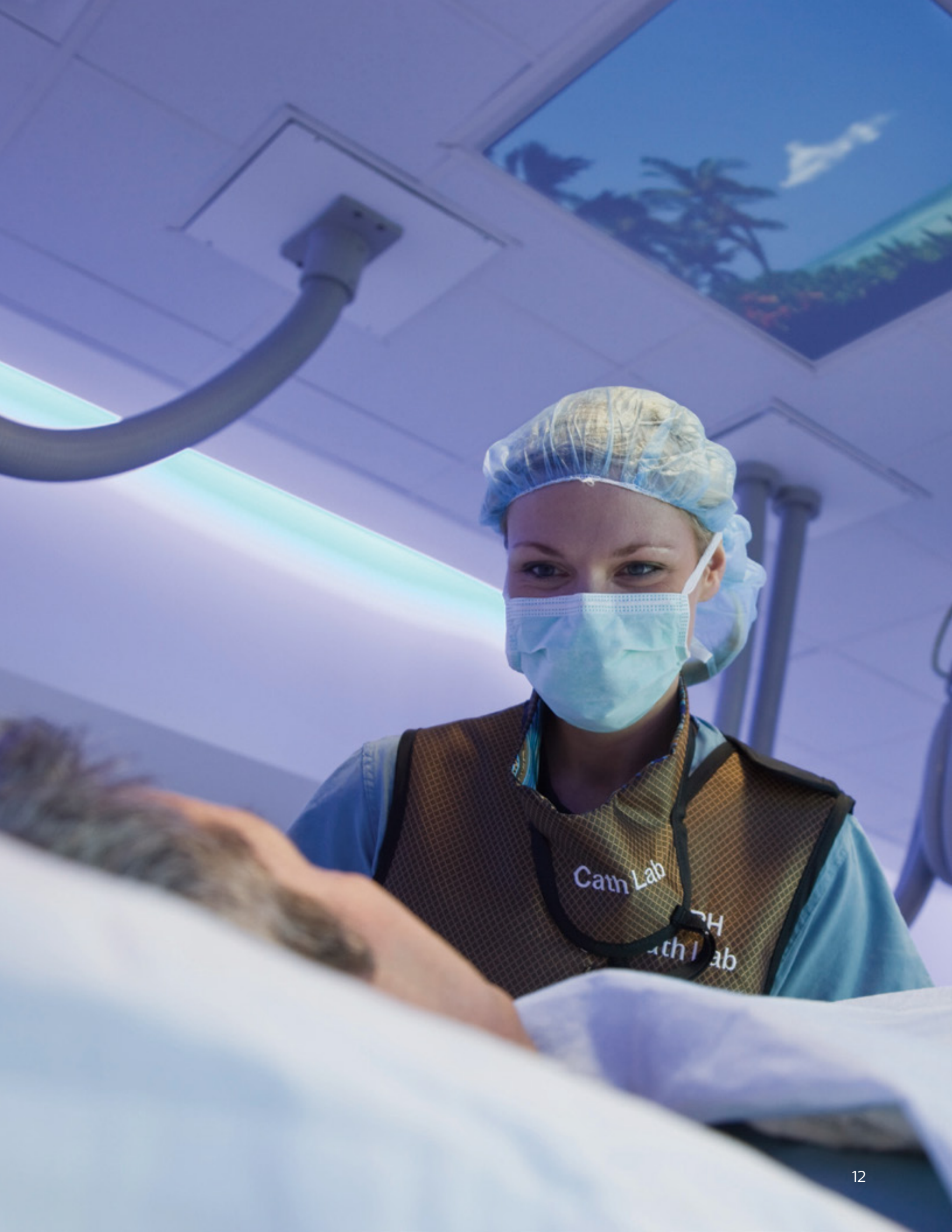- Such a management in the POSEIDON trial significantly reduced the incidence of CIN compared with the standard protocol (i.e., 6.7% vs. 16.3%)²⁴, and may constitute an excellent supplementary treatment in ultra-low contrast PCI.

Pre-procedure
3mL/kg
bolus

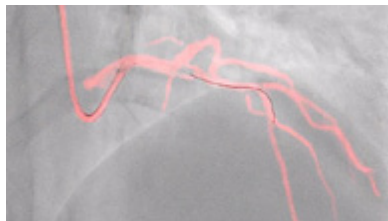
Post-procedure
LVDEP guided
rate x 4hrs

| LVDEP | Rate |
|-------|--------------|
| <13 | 5.0 ml/kg/hr |
| 13-18 | 3.0 ml/kg/hr |
| >18 | 1.5 ml/kg/hr |

Table relates to the post procedure



Philips unique solutions for ultra-low contrast PCI

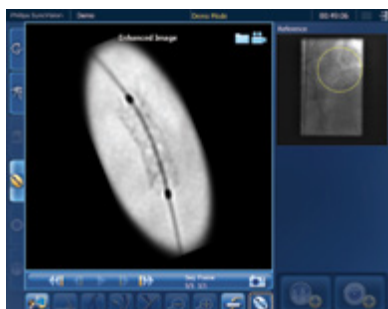
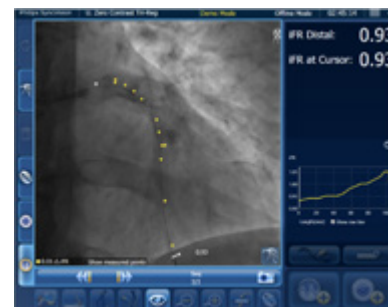

Dynamic Coronary Roadmap

A Philips exclusive technology, creates a dynamic, motion-compensated, real-time view of the coronary arteries. The system overlays a highlighted coronary angiogram on a 2D fluoroscopic image, creating a colored map that adjusts automatically, providing continuous and specific visual feedback on positioning of wires and catheters.

iFR Co-registration

Graphically displays the iFR drop along the angiogram, highlighting which portion of the vessel is ischemic.

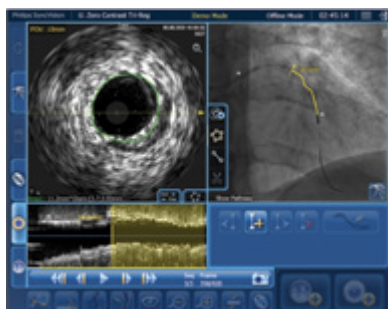
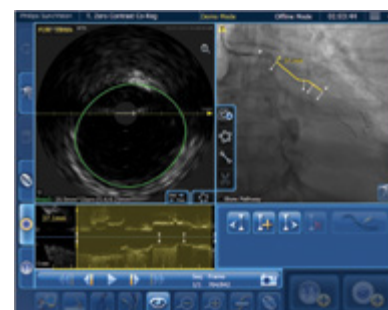

Device Detection

Enhanced live stent visualization, allows to quickly verify positioning both before and after deploying balloons, stents, and BVS devices, to display under-deployed stents, and to confirm fully expanded stents. It features instantaneous processing, eliminating the need to wait for new images before stent repositioning.

IVUS Co-registration

IVUS images obtained during pullback are merged with the corresponding angiogram obtained with the IVUS catheter in situ. Subsequently, information on the location of the imaging element within the vessel is derived during a manual pullback under continuous fluoroscopy. The presence of radiopaque markers in the IVUS catheter allows calculation of length correcting for vessel foreshortening

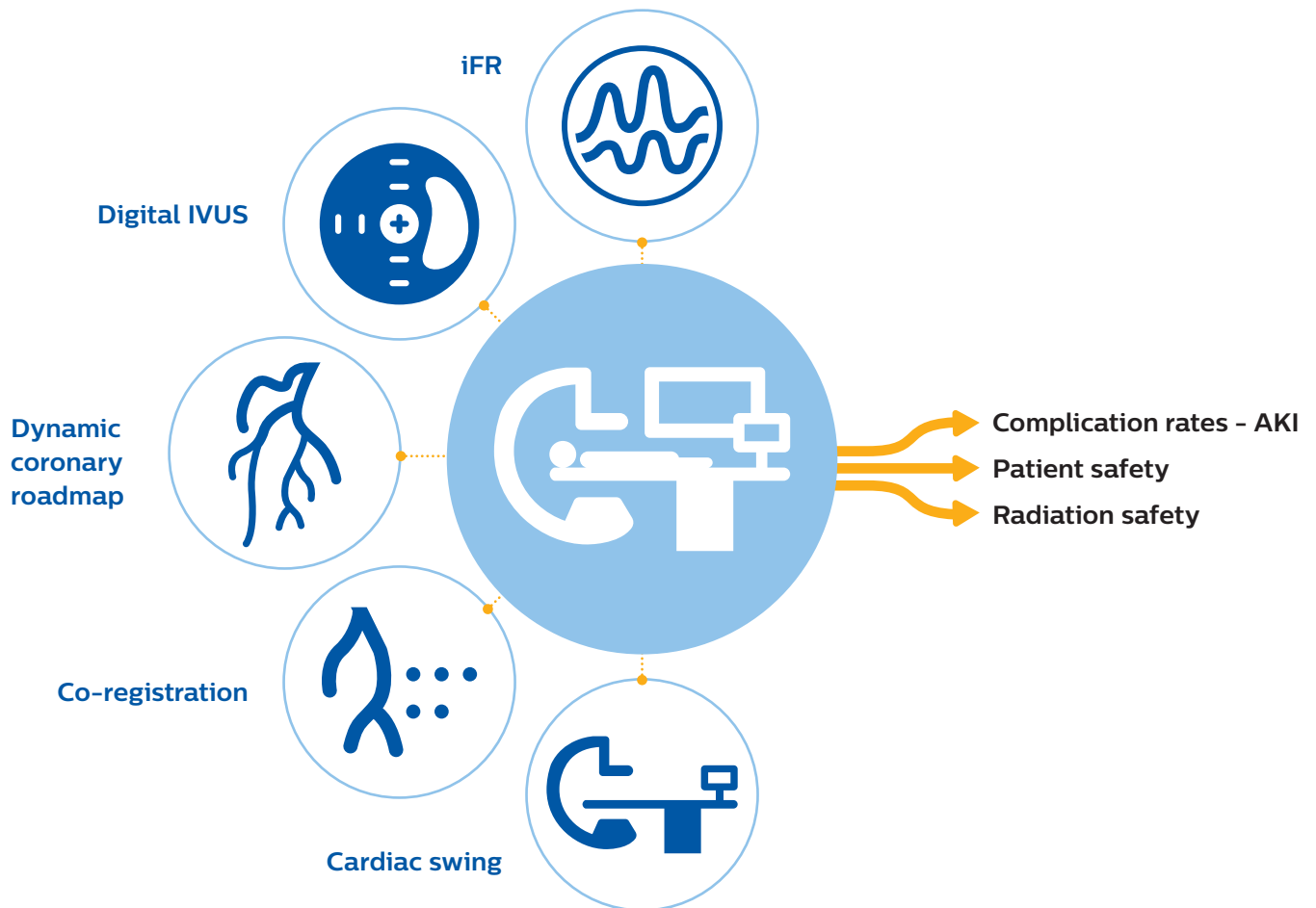


Tri-Registration

iFR data and IVUS images, collected during the pullback recordings, are merged within the same angiogram. iFR data, which are co-registered with the angiography image, are displayed into the roadmap picture and iFR drops dots, iFR value at cursor, and iFR Distal value are provided.

Technology to support contrast reduction

Philips's solution is PCI guidance, incorporating non-invasive and adjunctive imaging technologies, require less contrast median for proper diagnosis.



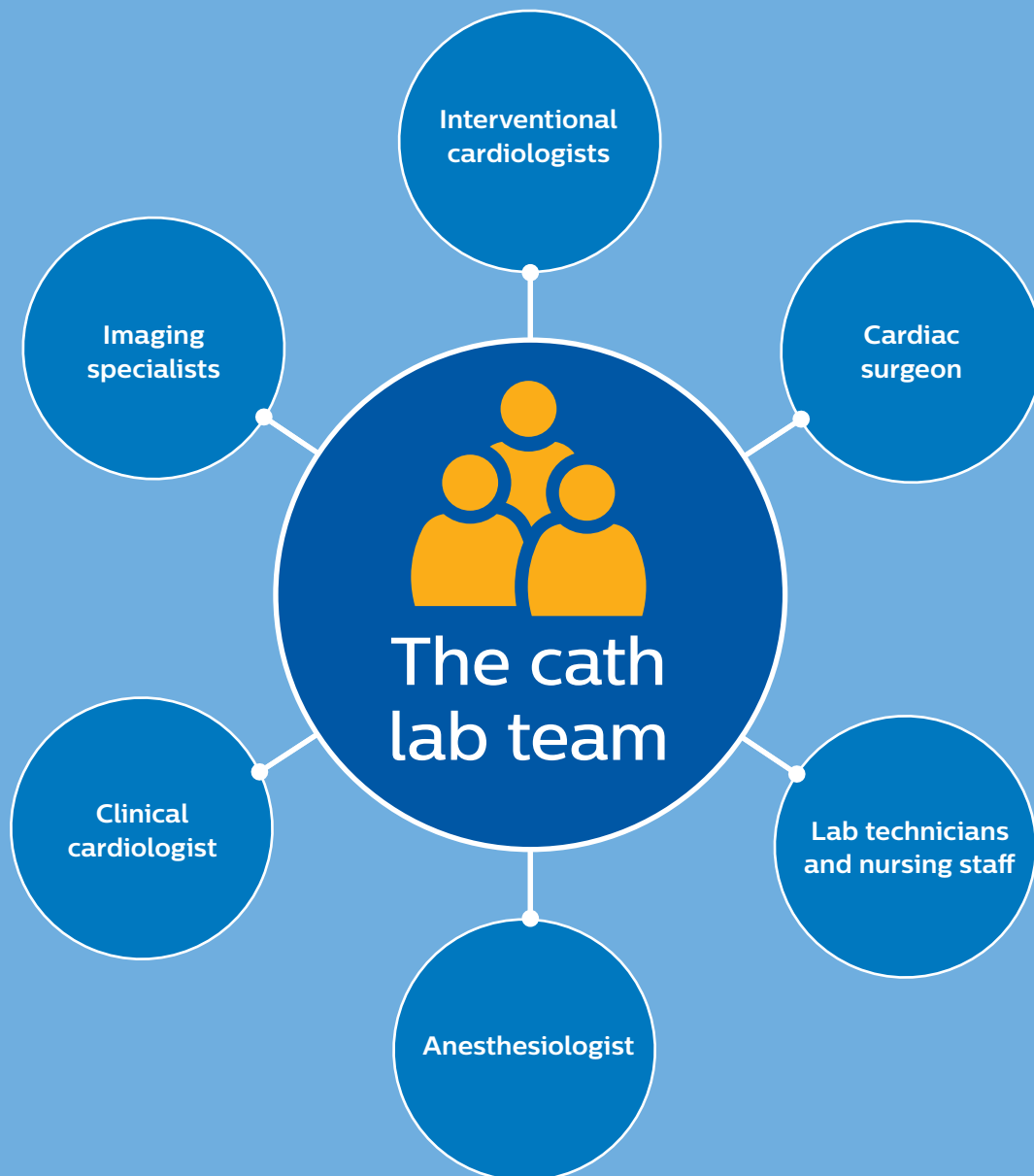
- Enables reduced contrast during PCI through the optimization of technology.
- Provides an alternative imaging plan for renal impaired patients.
- Allows more personalized care for high-risk cohorts.

The cath lab team



“You want to be starting off with the simpler lesions. It’s very useful to be learning the technique on standard PCI cases. The more you use co-registration the more you realize it’s going to be very beneficial to a wide variety of patients. What we found after using the Philips SyncVision system is that you can gradually use far less contrast in standard PCI cases. So, when you are faced with a high-risk ultra-low contrast case you have then got the skill set to do the case because this high-risk patient subset are not the cases you want to be learning the skills on. As with anything, practice, practice, practice. The more you do these cases with your team, the easier it becomes.”

Dr. Billal Patel, Head of Interventional Cardiology Lancashire Cardiac Centre, Blackpool, UK



The cardio-renal team



Interventional cardiologist

Learn how to perform ULC PCI:

- Enroll in the ULC PCI training program
- Practice the techniques with your cath lab team on simpler lesions first
- Communicate the availability of this service with your nephrologist



Nephrologist

What the nephrologist needs to know:

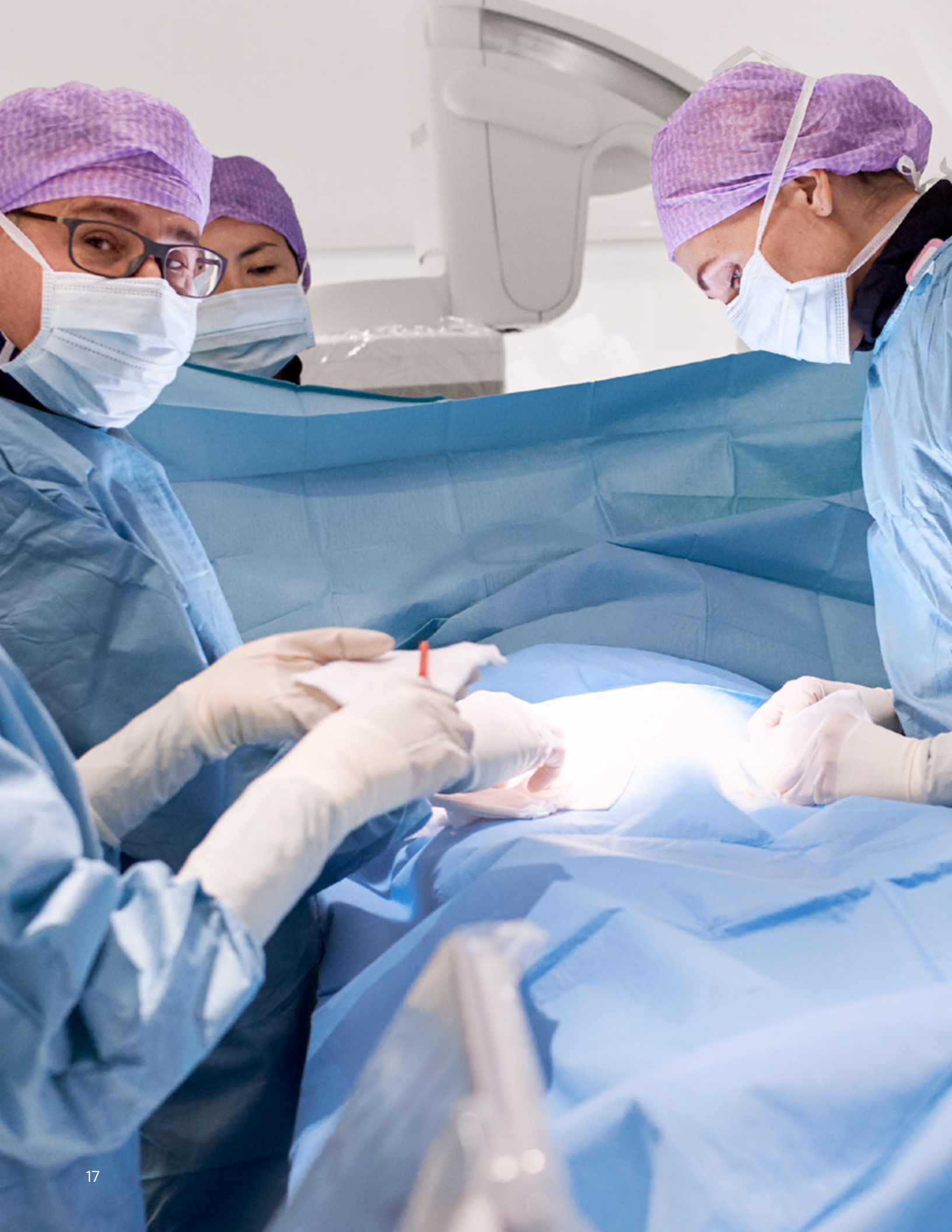- The IC can perform ULC PCI
- ULC PCI is a potential option for CKD patients



Cardiovascular team

Identify sub-specialists with an interest and make them aware of ULC PCI:

- Nurse practitioner
- General cardiologist (establish care)
- Preventative cardiologist (hypertension, hyperlipidemia)
- Heart Failure cardiologist (HFpEF, HFrEF, high output)
- Interventional cardiologist (CHIP)
- Electrophysiologist (AICD strategies)
- Pulmonary hypertension specialist (high output, systemic HT)
- Primary care physicians



1. MARKET INSIGHTS Interventional Cardiology Devices, DRG, United States, 2020. 39% of diagnostic angiographies are followed by PCI. 61% are not; Diagnosis of patients with angina and non-obstructive coronary disease in the catheter laboratory Rahman H., Corcoran D., Aetesam-Ur-Rahman M., Hoole S.P., Berry C., Perera D. *Heart* 2019 105:20 (1536-1542).
2. Doukky R, Diemer G, Medina A, Winchester DE, Murthy VL, Phillips LM, Flood K, Giering L, Hearn G, Schwartz RG, Russell R, Wolinsky D. Promoting appropriate use of cardiac imaging: no longer an academic exercise. *Ann Intern Med.* 2017; 166:438–440. doi: 10.7326/M16-2673.
3. Rajiah, P., Abbara, S., & Halliburton, S. S. (2017). Spectral detector CT for cardiovascular applications. *Diagnostic and interventional radiology (Ankara, Turkey)*, 23(3), 187–193. <https://doi.org/10.5152/dir.2016.16255>.
4. Mehran R, Aymong ED, Nikolsky E, et al. A simple risk score for prediction of contrast-induced nephropathy after percutaneous coronary intervention: development and initial validation. *J Am Coll Cardiol.* 2004; 44(7): 1393-1399. doi:10.1016/j.jacc.2004.06.068.
5. Mohammed, N. M., Mahfouz, A., Achkar, K., Rafie, I. M., & Hajar, R. (2013). Contrast-induced Nephropathy. *Heart views : the official journal of the Gulf Heart Association*, 14(3), 106–116. doi:10.4103/1995-705X.125926.
6. Wang, H. E., Muntner, P., Chertow, G. M., & Warnock, D. G. (2012). Acute kidney injury and mortality in hospitalized patients. *American journal of nephrology*, 35(4), 349–355. <https://doi.org/10.1159/000337487>.
7. Brown, J. R., Rezaee, M. E., Nichols, E. L., Marshall, E. J., Siew, E. D., & Matheny, M. E. (2016). Incidence and In-Hospital Mortality of Acute Kidney Injury (AKI) and Dialysis-Requiring AKI (AKI-D) After Cardiac Catheterization in the National Inpatient Sample. *Journal of the American Heart Association*, 5(3), e002739. <https://doi.org/10.1161/JAHA.115.002739>
8. Amin P, et al. Incremental cost of Acute Kidney Injury after Percutaneous Coronary Intervention in the United States. *AM J Cardiol.* 2020 Jan 1;125(1):29-331.
9. Hoste EAJ, Bagshaw SM, Bellomo R, et al. Epidemiology of acute kidney injury in critically ill patients: the multinational AKI-EPI study. *Intensive Care Med* 2015; 41:1411-23.
10. Odutayo A, Wong CX, Farkouh M, et al. AKI and long-term risk for cardiovascular events and mortality. *J Am Soc Nephrol* 2017;28:377-87.
11. Chertow et al. "Renalism": Inappropriately Low Rates of Coronary Angiography in Elderly Individuals with Renal Insufficiency. *J Am Soc Nephrol* 15: 2462-2468, 2004.
12. Weisbord S. AKI and Medical Care after Coronary Angiography: Renalism Revisited. *CJASN* November 2014, 9 (11) 1823-1825; DOI: <https://doi.org/10.2215/CJN.09430914>.
13. Panchal, Hemang B., "Impact of Chronic Kidney Disease on Revascularization and Outcomes in Patients with ST-Elevation Myocardial Infarction", *The American journal of cardiology* Publication date: 05/15/2021 .
14. Dudek et al "Ultra-low contrast coronary angiography and zero-contrast percutaneous coronary intervention for prevention of contrast-induced nephropathy: step-by-step approach and review", *Adv Interv Cardiol* 2019; 15, 2 (56): 127–136.
15. Kim JK, Kim NH, Shin IS, et al. Alteration of ventricular repolarization by intracoronary infusion of normal saline in patients with variant angina. *Korean Circ J* 2009; 39: 223-7. Jo SH, Youn TJ, Koo BK, et al. Renal toxicity evaluation and comparison between visipaque (iodixanol) and hexabrix (ioxaglate) in patients with renal insufficiency undergoing coronary angiography: The RECOVER study: a randomized controlled trial. *J Am Coll Cardiol* 2006; 48: 924-30.
16. Jo SH, Youn TJ, Koo BK, et al. Renal toxicity evaluation and comparison between visipaque (iodixanol) and hexabrix (ioxaglate) in patients with renal insufficiency undergoing coronary angiography: The RECOVER study: a randomized controlled trial. *J Am Coll Cardiol* 2006; 48: 924-30.
17. Sherwin PF, Cambron R, Johnson JA, Pierro JA. Contrast doseto-creatinine clearance ratio as a potential indicator of risk for radiocontrast-induced nephropathy: correlation of D/CrCL with area under the contrast concentration-time curve using iodixanol. *Invest Radiol* 2005; 40: 598-603.
18. McCullough PA, Bertrand ME, Brinker JA, Stacul F. A meta-analysis of the renal safety of isosmolar iodixanol compared with low-osmolar contrast media. *J Am Coll Cardiol* 2006; 48: 692-9.
19. Nayak KR, Mehta HS, Price MJ, et al. A novel technique for ultra- low contrast administration during angiography or intervention. *Catheter Cardiovasc Interv* 2010; 75: 1076-83.
20. Ali ZA, Karimi Galougahi K, Nazif T, et al. Imaging- and physiology-guided percutaneous coronary intervention without contrast administration in advanced renal failure: a feasibility, safety, and outcome study. *Eur Heart J* 2016; 37: 3090-5.
21. Sacha J, Feusette P. How should I treat unprotected LM stenosis in a patient with ACS who develops a severe contrast-induced nephropathy after coronary angiography? https://www.pcronline.com/Cases-resources-images/Cases/EIJ-HSIT/Treatment-strategy-for-left-main-stenosis-in-patient-with-CIN?auth=true#comments_area (Published, 06 December 2017).
22. Sacha J, Feusette P. Zero-contrast percutaneous coronary intervention of saphenous vein graft in a patient with chronic renal failure. *Adv Interv Cardiol* 2018; 14: 309-311.
23. Karimi Galougahi K, Zalewski A, Leon MB, et al. Optical coherence tomography-guided percutaneous coronary intervention in pre-terminal chronic kidney disease with no radio-contrast administration. *Eur Heart J* 2016; 37: 1059.
24. Sacha J. Marking wire technique for zero-contrast percutaneous coronary interventions. *Adv Interv Cardiol* 2018; 14: 204-5.
25. Brar SS, Aharonian V, Mansukhani P, et al. Haemodynamic-guided fluid administration for the prevention of contrast-induced acute kidney injury: the POSEIDON randomised controlled trial. *Lancet* 2014; 383: 1814-23.

