



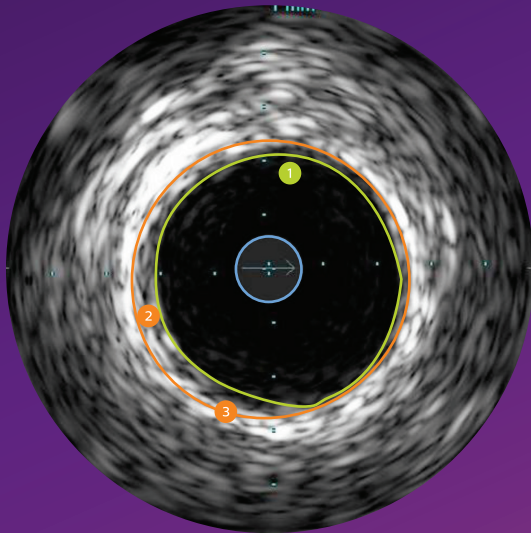
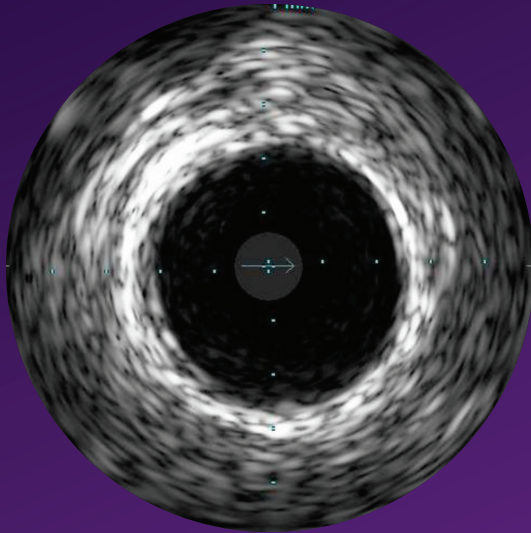
PHILIPS

Eagle Eye **Platinum**

RX digital IVUS catheter

IVUS image interpretation

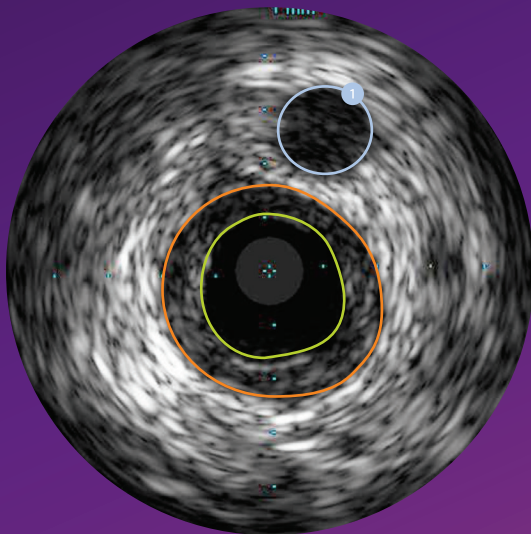
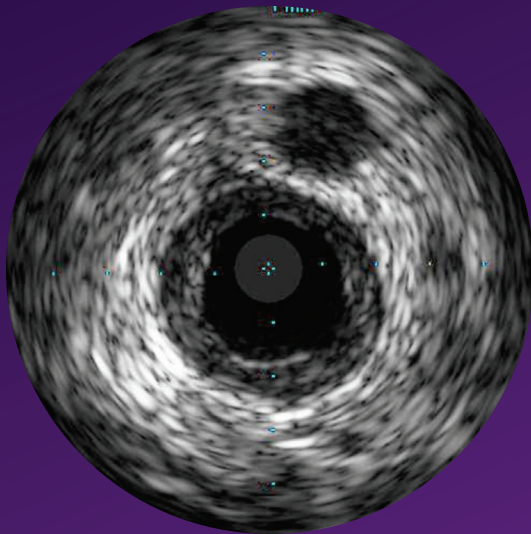
Pocket guide



Normal vessel

- In a normal vessel, the lumen border is almost indistinguishable from the vessel border. While IVUS allows visualization of vessel and lumen, angiograms only provide a shadow of the lumen. In patients with diffuse disease, relying on the angiogram can potentially lead to underestimation of stenosis.
- Lumen border is drawn inside the intima or plaque.
- Intimal layer is normally not seen unless it has begun to thicken.
- Vessel border is drawn just inside the adventitia, which appears as a bright white ring due to highly reflective collagen sheets.
- The catheter mask (blue area) indicates the location of the ultrasound transducer.

- 1 Lumen border
- 2 Intimal thickening
- 3 Vessel border



Concentric mixed plaque

- Concentric plaques are distributed circumferentially in the vessel.
- Concentric plaques tend to occur in areas of negative remodeling; use of angiography alone could result in too large a stent diameter.
- Mixed plaque is a combination of tissues of varying echogenicity. The distribution of light and dark may be distinct, or light and dark variations may be intermingled as shown here.
- $MLA < 4 \text{ mm}^2$ in LAD, LCX, and RCA vessels $> 3 \text{ mm}$ in diameter correlates with physiological significance.¹
- $MLA < 6 \text{ mm}^2$ in left main correlates with $FFR < 0.75$ indicating physiological significance.^{1, 2, 3}
- Nearby vessels on the periphery can be seen moving in and out of the field of view and can be used as landmarks.

1 Nearby vessel

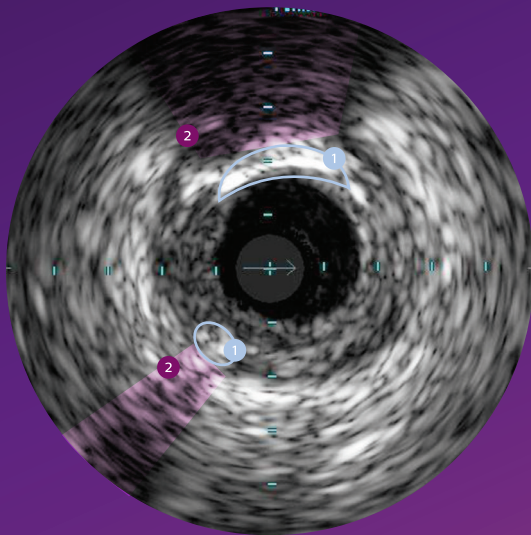
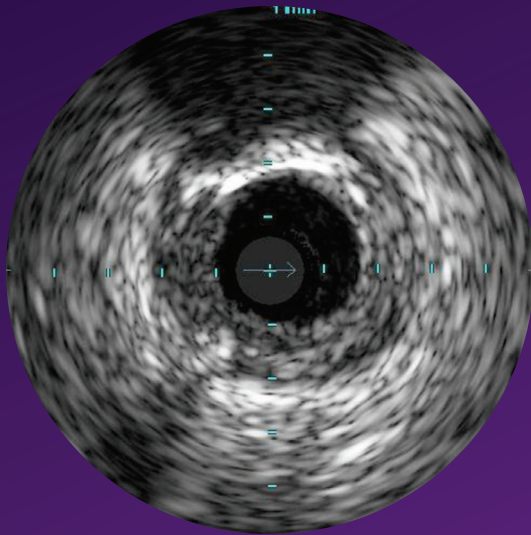
1. Jasti, et al. Correlations between Fractional Flow Reserve and Intravascular Ultrasound in Patients with an Ambiguous Left Main Coronary Artery Stenosis, *Circulation*, 2004; 110: 2831-2836
2. Jose M. de la Torre Hernandez et al. Prospective Application of Pre-Defined Intravascular Ultrasound Criteria for Assessment of Intermediate Left Main Coronary Artery Lesions: Results From the Multicenter LITRO Study, *J Am Coll Cardiol*, 2011 58: 351-358.
3. Levine et al. 2011 ACCF/AHA/SCAI Guideline for Percutaneous Coronary Intervention. *J Am Coll Cardiol*, 2011; 58:44-122

Eccentric mixed plaque

- Eccentric plaques are distributed non-circumferentially in the vessel; this makes the assessment of disease by angiography especially prone to underestimation or overestimation depending on the angle of view.
- Calcium is indicated by very bright areas with acoustic shadowing that blocks out the image behind. This shadowing occurs because the high density of calcium dampens the ultrasound echo.
- VH IVUS* imaging can provide a more detailed and objective view of plaque composition (see pages 23–24).

- 1 Echolucent plaque
- 2 Echogenic plaque
- 3 Calcium
- 4 Acoustic shadowing

*Safety and effectiveness of VH IVUS for use in the characterization of vascular lesions and tissue types has not been established

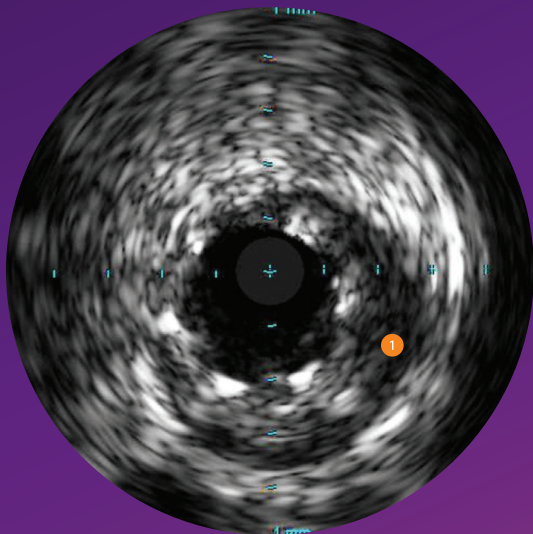
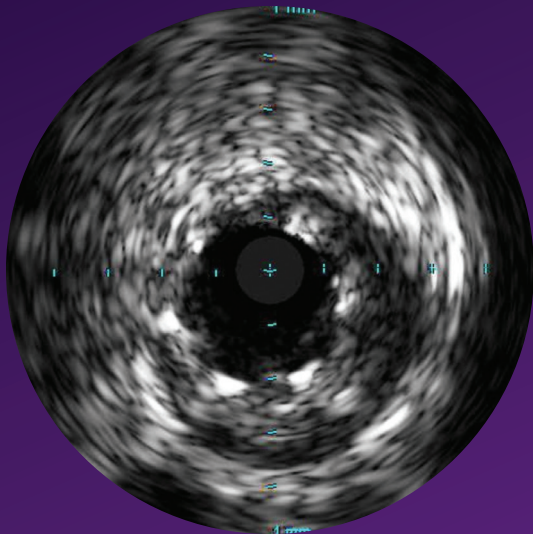


Plaque with calcium

- The calcium in this plaque produces two arcs of acoustic shadowing.
- Calcium is indicated by very bright areas with acoustic shadowing that blocks out the image behind. This shadowing occurs because the high density of calcium prevents the ultrasound from passing through.
- Detection of calcium is a critical factor in determining the optimal PCI strategy.
- Calcium is not always seen on the angiogram. In carotid cases angiography can fail to identify calcium 46% of the time.¹
- Nearby vessels on the periphery can be seen moving in and out of the field of view and can be used as landmarks.

- 1 Calcium
- 2 Acoustic shadowing

1. Diethrich et al. *Journal of Endovascular Therapy*, 2007; 14:676-686



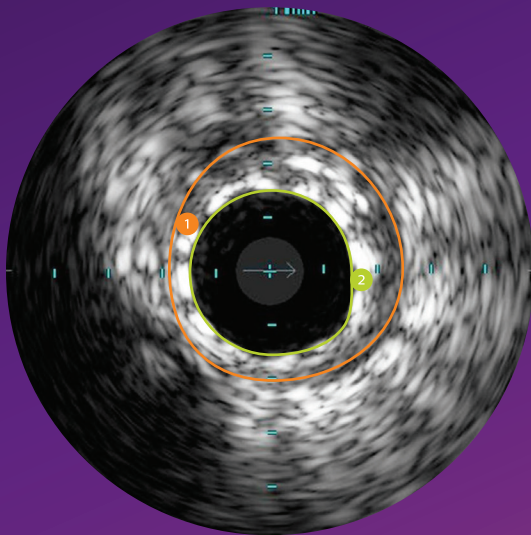
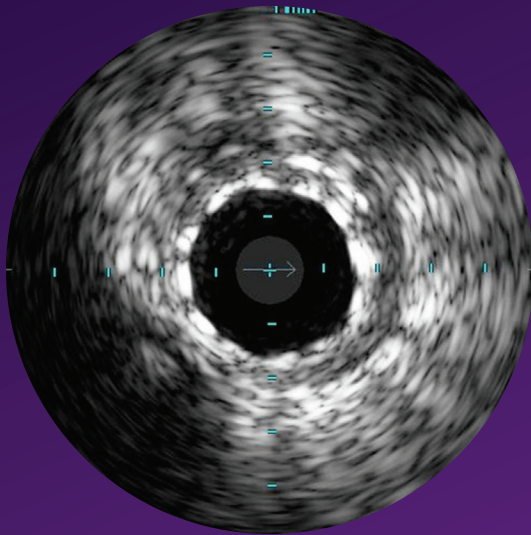
Under-expanded stent following high pressure ballooning

- Stent struts appear as bright marks spaced around the lumen (six struts seen here).
- Large presence of plaque behind stent struts may indicate under-expansion. This stent remained under-expanded even after a high pressure balloon was used.
- In this case, too small a stent was chosen and the high pressure balloon did not solve the problem. IVUS can be used to inform selection of a larger stent size.
- Stent under-expansion is associated with stent thrombosis, TLR, and MACE.^{1, 2}

1 Area of under-expansion

1. Fujii et al, JACC, 2005 Apr 5; 45(7):995-8

2. Chenu, Pichard, et al. AJC 2005;95:1240-2



Stent with complete apposition

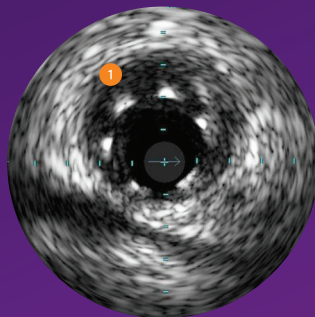
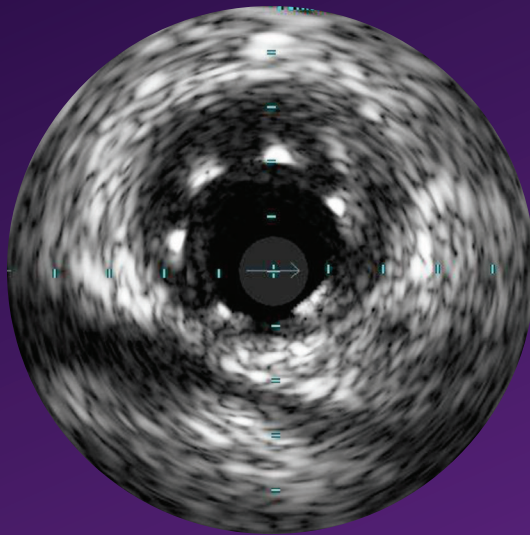
- Complete apposition is indicated by consistent stent strut contact with tissue.
- Complete apposition does not guarantee that a stent is not under-sized or under-expanded.

- ① Area showing complete apposition
- ② Lumen border

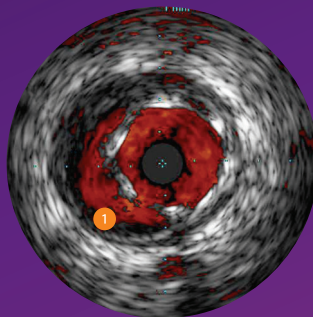
Stent with malapposition

- Malapposition is indicated by blood visible behind stent struts.
- Blood may appear as a very faint speckle or black on grayscale IVUS.
- Blood flow will appear red with ChromaFlo imaging.
- Stents may be completely or only partially malapposed depending on how much of the stent is in contact with the lumen wall.

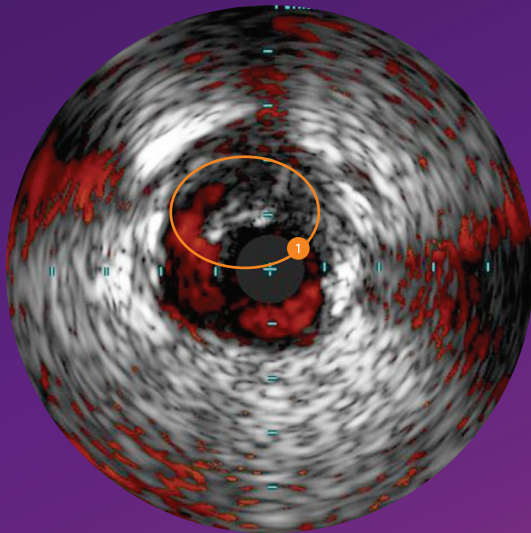
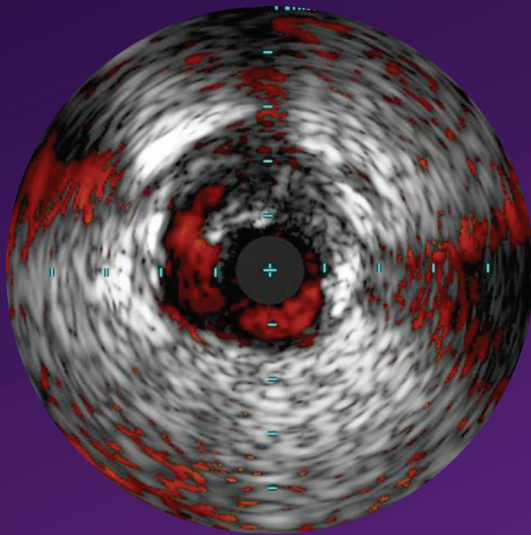
1 Blood behind struts indicates malapposition



Grayscale



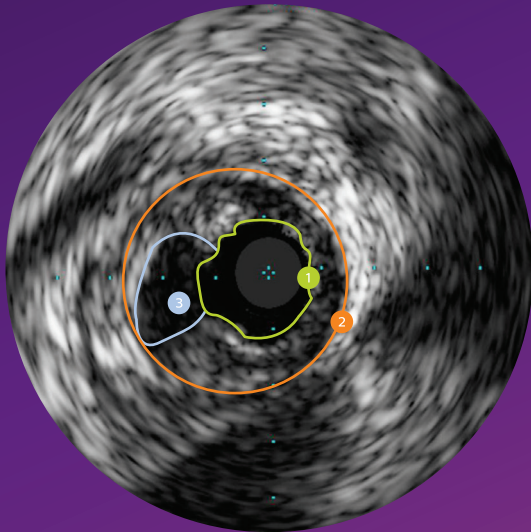
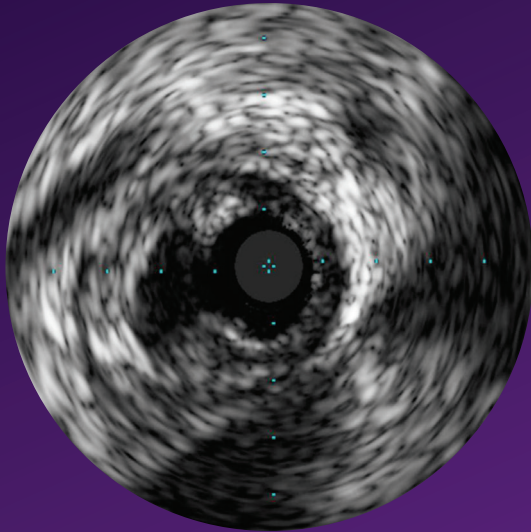
ChromaFlo



Dissection

- A dissection, or tear in the vessel wall, can be seen as a flap with blood flow behind it.
- ChromaFlo imaging, shown here, enhances identification of dissection flaps by verifying presence of blood flow (in red) behind the flap.

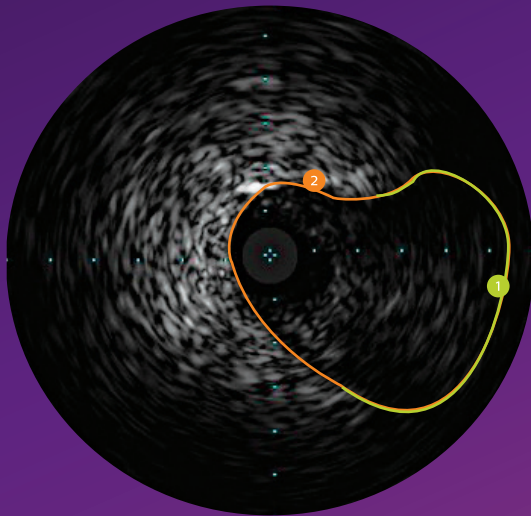
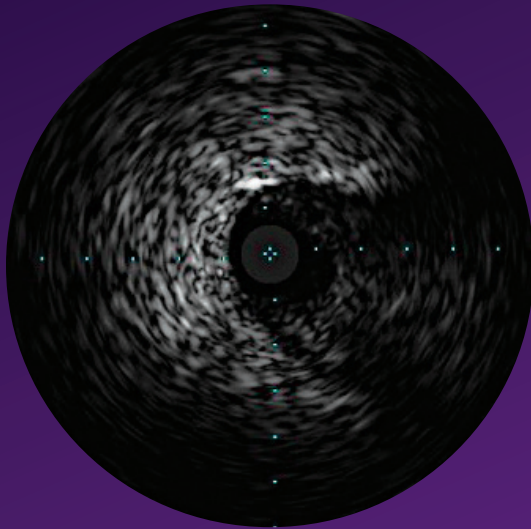
1 Dissection flap



Plaque rupture

- Plaque ruptures are typically seen proximal to a significant lesion and may have been the original culprit of the lesion.
- To distinguish a plaque rupture from a dissection, determine whether there is a dissection flap or a stationary irregularity in the lumen wall.

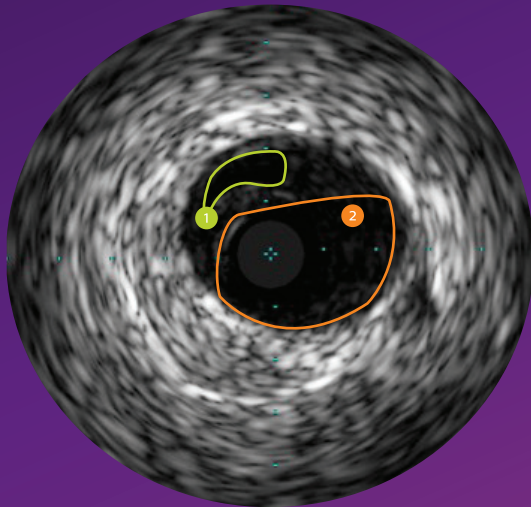
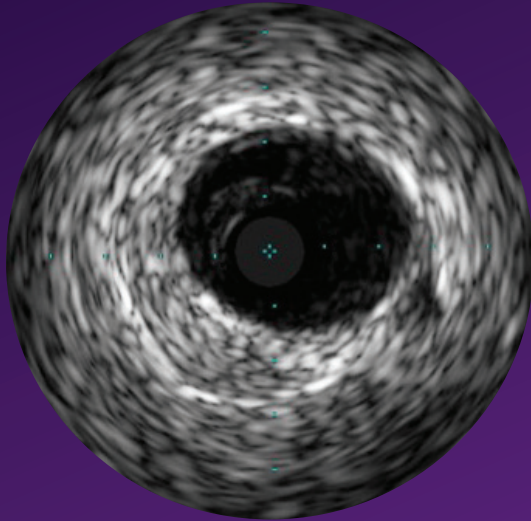
- 1 Lumen border
- 2 Vessel border
- 3 Plaque rupture site



Proximal cap

- When a proximal cap is located near a side branch, the IVUS catheter can be positioned in the side branch to view and confirm the location of the proximal cap.
- As a wire penetrates the cap, IVUS can confirm wire position.

- 1 The border of the proximal cap
- 2 The border of the side branch



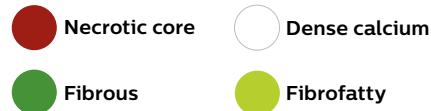True and false lumen

- IVUS can help confirm wire position in the true or false lumen.
- The true lumen is often compressed by the false lumen.

- ① Compressed true lumen (separate echolucent area)
- ② False lumen

VH IVUS imaging

- VH IVUS imaging classifies plaque into four tissue types.¹

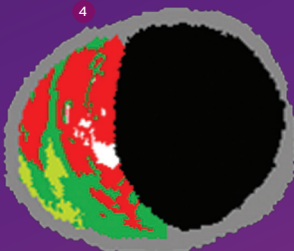
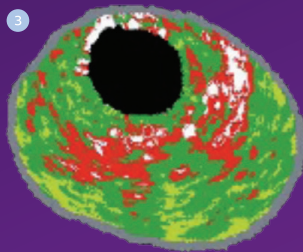
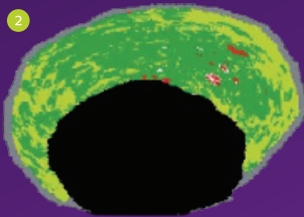
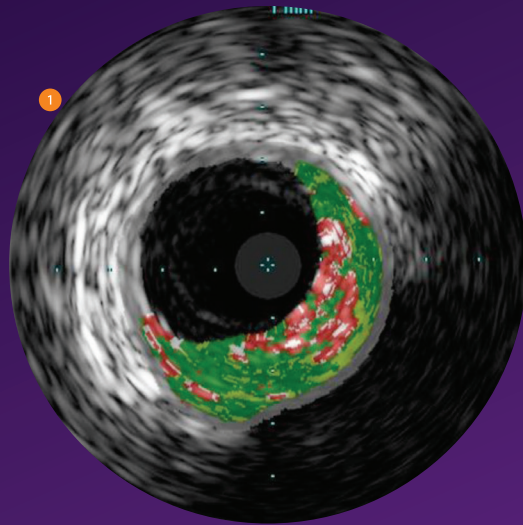


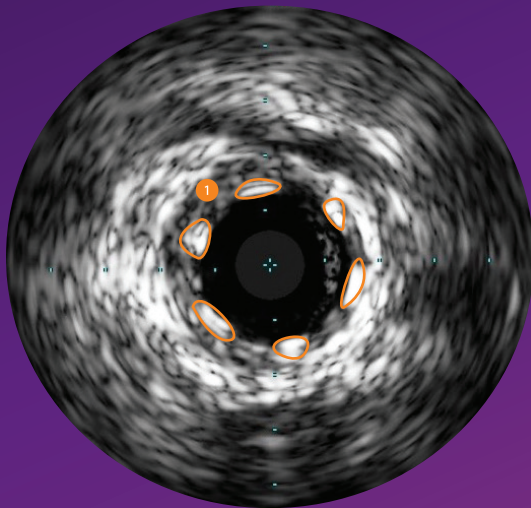
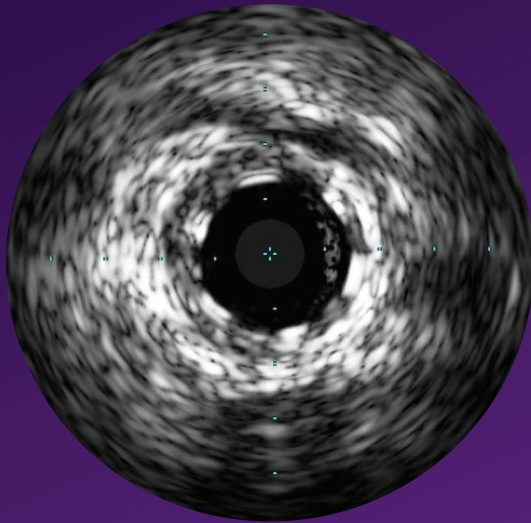
- Based on 15 years of research with over 200 scientific publications.
- Used in multiple clinical studies including the landmark PROSPECT study of 700 ACS patients published in the New England Journal of Medicine.
- PROSPECT results demonstrated that VH IVUS adds valuable information for physicians to determine lesion risk profile.²

- 1 Complete lesion assessment
- 2 Pathological intimal thickening (PIT)
- 3 Calcified fibroatheroma
- 4 Thin cap fibroatheroma (TCFA)

1. Nair A et al. Automated coronary plaque characterisation with intravascular ultrasound backscatter: ex vivo validation. *EuroInterv* 2007; 3:113-120.
2. Stone et al. A prospective natural history study of atherosclerosis. *N Engl J Med* 2011;364:226-35.

Safety and effectiveness of VH IVUS for use in the characterization of vascular lesions and tissue types has not been established.

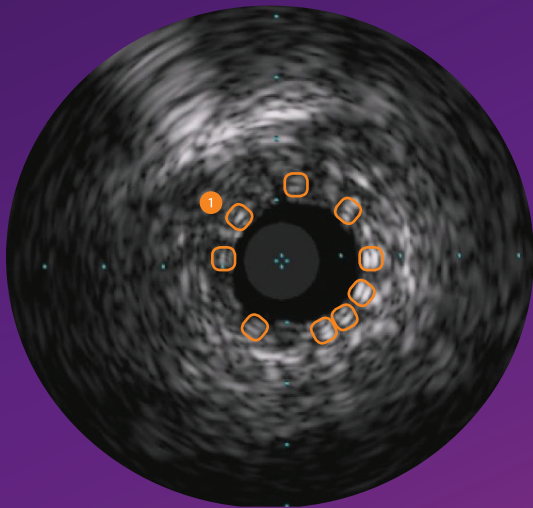
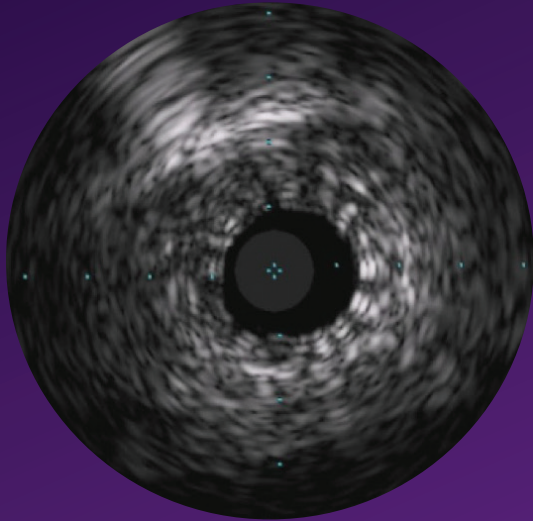




Bioresorbable scaffold, well apposed

- Because of the thickness and material of the struts, it is common for the struts to present on ultrasound as a double line representing the leading and trailing edges of the strut.
- IVUS may be used to optimize BRS implantation by allowing you to observe: scaffold expansion, apposition, edge complications.

1 BRS, well apposed



Bioresorbable scaffold, in small vessel

 BRS in small vessel

See more with IVUS

Stent sizing

Angiography	IVUS
Must rely on “eyeball” estimate	Enables you to make lumen and reference vessel measurements that can be used when selecting stent size

Stent expansion and apposition

Angiography	IVUS
Cannot see the vessel wall to verify optimal placement	User-defined cross-sectional area measurements and views, allow verification and documentation of optimal stent placement

Normal vessels vs. diffuse disease

Angiography	IVUS
Tends to underestimate degree of stenosis in diffuse disease or with positive remodeling ¹	Helps you distinguish normal from abnormal vessels and find the source of symptoms in patients with a normal angiogram

Concentric and eccentric plaques

Angiography	IVUS
Must rely on “eyeball” estimate; assessment of eccentric plaque lesion size especially prone to error based on angle of view	Helps you get an accurate lumen area to determine lesion significance and stent size

Calcium

Angiography	IVUS
Can fail to identify calcium 46% of the time ²	Makes the presence of calcium clear, helping to identify lesions that need pre-treatment

Plaque rupture, dissection

Angiography	IVUS
Cannot be determined	Can be determined

1. Reference vessels are diseased 93% of the time. Mintz et al. *JACC* 25;7:1479–85, June 1995.

2. Diethrich et al. *Journal of Endovascular Therapy*, 2007; 14:676–686.



Philips

3721 Valley Centre Drive, Suite 500
San Diego, CA 92130 USA
www.philips.com/IGTdevices

© 2019 Koninklijke Philips N.V. All rights reserved.
Approved for external distribution.
D041485-01 042019