

# Excimer Laser Coronary Atherectomy for the Treatment of a Calcified Lesion

## OPERATOR / FACILITY

Antonis Pratsos, MD  
Bryn Mawr Hospital,  
Main Line Health System  
Bryn Mawr, Pennsylvania

## Case History

- 89-year-old female
- History: Dyslipidemia and CAD, CABGx4, positive stress test, chest pain, family history of CAD.

## Angiography

- RCA patent
- Occluded SVG to RCA
- LIMA to LAD patent
- SVG to OM1 minor luminal irregularities
- SVG to Circumflex patent

## Intervention

- SVG to RCA engaged with an 8F MP guide
- 0.014" BMW wire was inserted into the SVG to RCA
- 0.9mm X80 catheter was used at 50 fluence and 40 Hz, post laser revealed TIMI 3 flow with residual stenosis and evidence of thrombus in distal SVG. Therefore, a 1.4mm ELCA was used at 60/40.
- Post Laser a Filterwire EZ was placed in the distal SVG
- PTCA was performed, with a 3x18mm Quantum Maverick balloon at 16 ATM
- Stent deployment, 3.5x23mm Xience was deployed in the Proximal SVG to RCA at 22 ATMS
- Post dilation with a 3x18 Maverick was performed at 24 ATMS

## DEVICES

### Guide

- 8F MP4 (Boston Scientific®)

### Wire

- 0.014" Filterwire EZ (Boston Scientific®)
- 0.014" BMW (Abbott Vascular®)

### Lasers

- 0.9mm and 1.4 mm ELCA® (Spectranetics®)

### Balloons

- 3x18mm Quantum Maverick® (Boston Scientific®)
- 3x18mm Maverick® (Boston Scientific®)

### Stents

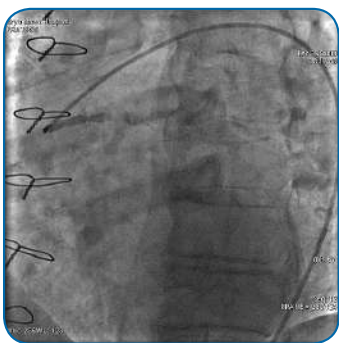
- 3.5x23mm Xience® (Abbott Vascular®)

### Anticoagulation

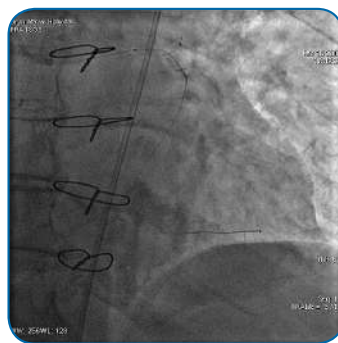
- Integrilin® (Millennium® Pharmaceuticals)

## FEATURED SPECTRANETICS PRODUCTS

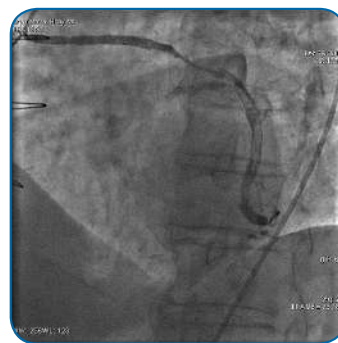
- ELCA® Coronary Laser Atherectomy Catheter



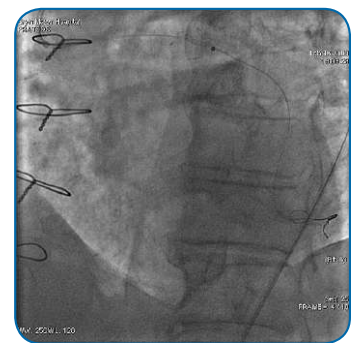
SVG 1



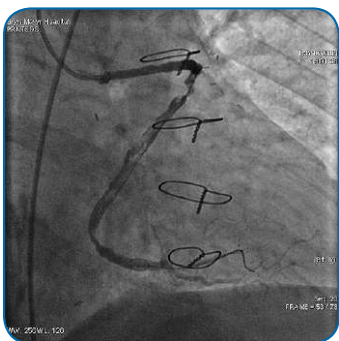
SVG with 0.9



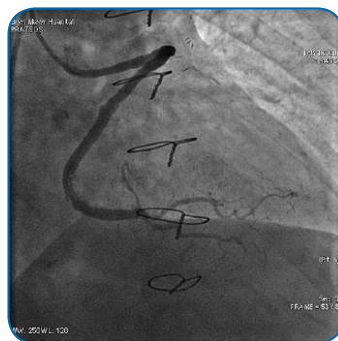
SVG post 0.9



SVG 1.4mm ELCA



SVG with Filterwire EZ



SVG Final

## Excimer Laser Coronary Atherectomy for the Treatment of a Calcified Lesion

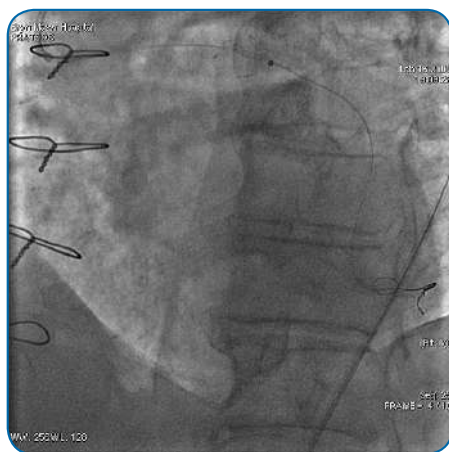
### Results / Conclusions

- The excimer laser was used to treat the occluded SVG, restoring flow to the RCA
- The excimer laser allowed for the placement of an embolic protection device in an occluded SVG, enabling distal protection for the remainder of the case
- Post excimer laser ablation TIMI 3 flow was restored
- Stent placement in the proximal SVG to RCA

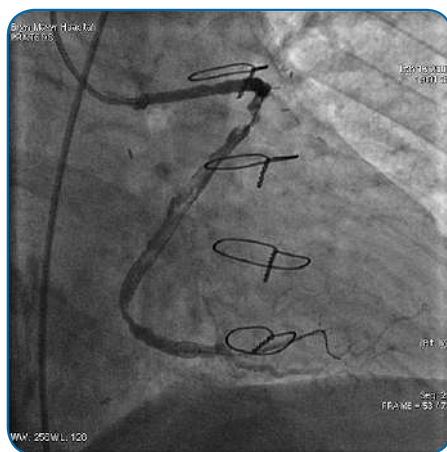
*The use of excimer laser ablation in a occluded SVG restored flow and allowed for the delivery of a distal protection device resulting in a great outcome.*

– Antonis Pratsos, MD

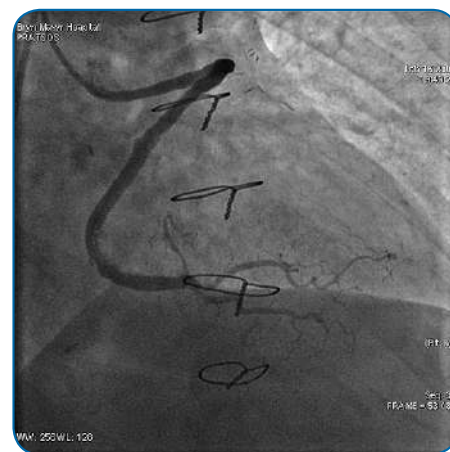
At the time of publication, Dr. Pratsos has a consulting agreement with Spectranetics.



SVG 1.4mm ELCA



SVG with Filterwire EZ



SVG Final

### Important Safety Information

#### ELCA® Coronary Laser Ablation Catheter

##### INDICATIONS

The Laser Catheters are intended for use either as a stand-alone modality or in conjunction with Percutaneous Transluminal Coronary Balloon Angioplasty (PTCA) in patients who are acceptable candidates for coronary artery bypass graft (CABG) surgery. The following Indications for Use, Contraindications and Warnings have been established through multicenter clinical trials. The Spectranetics CVX-300® Excimer Laser System and the multifiber laser catheter models are safe and effective for the following indications:

- Occluded saphenous vein bypass grafts.
- Ostial lesions.
- Long lesions – (greater than 20mm in length).
- Moderately calcified stenoses.
- Total occlusions traversable by a guidewire.
- Lesions which previously failed balloon angioplasty.

These lesions must be traversable by a guidewire and composed of atherosclerotic plaque and/or calcified material. The lesions should be well defined by angiography.

##### CONTRAINDICATIONS

- Lesion is in an unprotected left main artery.
- Lesion is beyond acute bends or is in a location within the coronary anatomy where the catheter cannot traverse.
- Guidewire cannot be passed through the lesion.
- Lesion is located within a bifurcation.
- Patient is not an acceptable candidate for bypass graft surgery.

See complete IFU for more information before attempting use of ELCA.

##### WARNINGS

Federal (USA) law restricts this device to sale by or on the order of a physician with appropriate training. A clinical investigation of the Spectranetics CVX-300® Excimer Laser System did not demonstrate safety and effectiveness in lesions amenable to routine PTCA or those lesions not mentioned in the Indications for Use, above. The effect of adjunctive balloon angioplasty on restenosis, as opposed to laser alone, has not been studied. The use of the CVX-300® Excimer Laser System is restricted to physicians who are trained in the use of the product.

##### PRECAUTIONS

This device has been sterilized using Ethylene Oxide and is supplied STERILE. The device is designated and intended for SINGLE USE ONLY and must not be resterilized and/or reused. Store in a cool, dry place. Protect from direct sunlight and high temperatures (greater than 60°C or 140°F). During the procedure, appropriate anticoagulant and coronary vasodilator therapy must be provided to the patient. Anticoagulant therapy should be administered per the institution's PTCA protocol for a period of time to be determined by the physician after the procedure. Percutaneous Excimer Laser Coronary Atherectomy (ELCA) should be performed only at hospitals where emergency coronary bypass graft surgery can be immediately performed in the event of a potentially injurious or life-threatening complication. The results of clinical investigation indicated that patients with the following conditions are at a higher risk for experiencing acute complications:

- Patients with diabetes.
- Patients with a history of smoking.
- Lesions with tortuous vessels.