

PHILIPS

Ultrasound

Clinical case study

The eL18-4 PureWave linear array with MicroFlow Imaging (MFI) in diagnosis of breast abnormalities

eL18-4 PureWave linear array transducer

Category

Breast Assessment

Authors

Lynwood W. Hammers, DO
Consultant Radiologist

Hammers Healthcare Imaging, LLC
New Haven, CT

Overview

Diagnostic ultrasound is the complementary modality to mammography for evaluation of women with dense breast tissue. It is of significant value in evaluating palpable masses and has been utilized as a screening modality for women with dense breast tissue and for needle guidance for biopsies.

Patient history

The patient was a 59-year-old female with dense breast tissue on a mammogram with the suggestion of a mass in the right upper outer quadrant. There was no family history of breast cancer. The patient was sent for ultrasound assessment and biopsy if indicated.

Protocol

All quadrants of the right and left breast were scanned using a conventional linear array transducer and the eL18-4 transducer to evaluate breast echogenicity, the presence and vascularity of masses, and assessment of the mammary ducts and lymph nodes. The findings from the two transducers were compared.

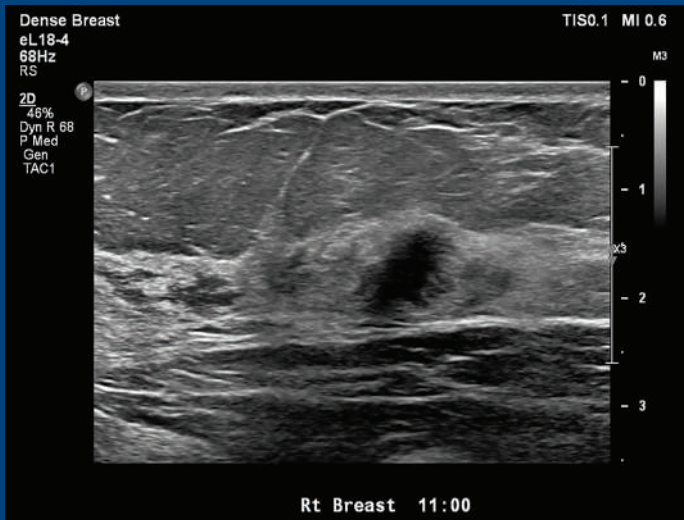
Findings

Both conventional and eL18-4 transducers revealed a hypoechoic mass. Spiculations were best seen on the eL18-4. The mass was in echogenic fibroglandular tissue and lay adjacent to underlying muscle. This mass was taller than wide, without calcification. This was a Birads 5 mass, and biopsy was suggested.

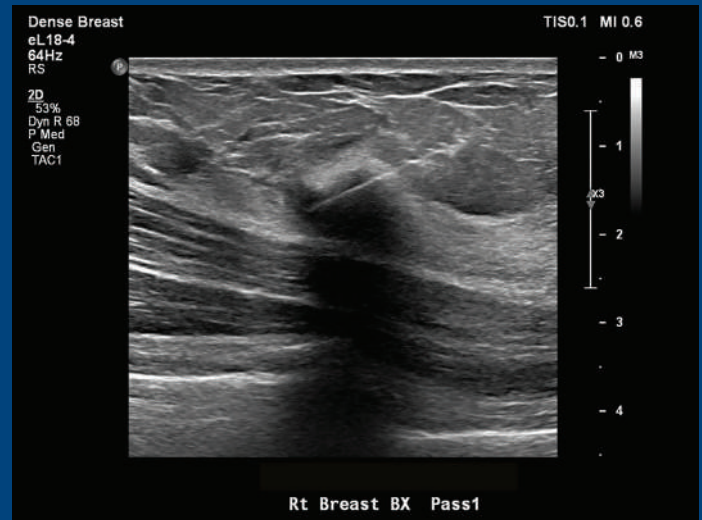


The Philips eL18-4 PureWave linear array transducer is our first high-performance transducer featuring ultra-broadband PureWave crystal technology with multi-row array configuration, allowing for fine-elevation focusing capability.

Clinical case study: The eL18-4 PureWave linear array with MicroFlow Imaging (MFI) in diagnosis of breast abnormalities



View of a breast mass using the eL18-4 transducers.



Imaging using eL18-4 transducer to guide the needle.

Conclusion

Although the mass was classic for breast cancer, the fine spiculations on the eL18-4 were strongly suggestive that there was invasion into the adjacent soft tissue consistent with invasive ductal cancer. No definite muscular invasion was seen on the eL18-4 or at surgery. The mass was an invasive ductal cancer.

With the advent of linear array transducers, breast ultrasound has become a major complementary, inexpensive modality to screening mammograms. Connecticut was the first state to pass a law mandating coverage for screening breast ultrasound for women found to have dense breast tissue on mammography.

Ultrasound not only picks up masses not seen on mammography, it provides a higher negative predictive value to decrease unnecessary biopsies.¹ It is the visualization of these small spiculations that increases the sensitivity of the diagnosis.

More precise localization of the biopsy needle was provided by the eL18-4 transducer.

Reference

- 1 Taylor KJW, Merritt C, Piccoli C, Schmidt R, Rouse G, Fornage B, Rubin E, Georgian-Smith D, Winsberg F, Goldberg B, Mendelson E. Ultrasound as a complement to mammography and breast examination to characterize breast masses. *Ultrasound in Medicine and Biology*. 2002;28(1).

Results from case studies are not predictive of results in other cases. Results in other cases may vary.