

NEONATAL X-RAY

IMAGE QUALITY AND SHARING GOOD PRACTICE

Chest and Abdomen

Stephanie French – Senior Radiographer Leeds General Infirmary

Background

- Radiographs are an essential diagnostic tool in neonatal medicine (Arthur 2001)
- It is crucial that any staff who are involved with the imaging process are:
 - Aware of their roles and responsibilities to ensure the safety of staff, visitors and the infant (IRR 17 & IR(ME)R 17)
 - Use good technique
 - Promote optimal image quality
 - Ensure that the infant is not exposed to any/ minimal environmental stress, as a result of increased handling and position changes.

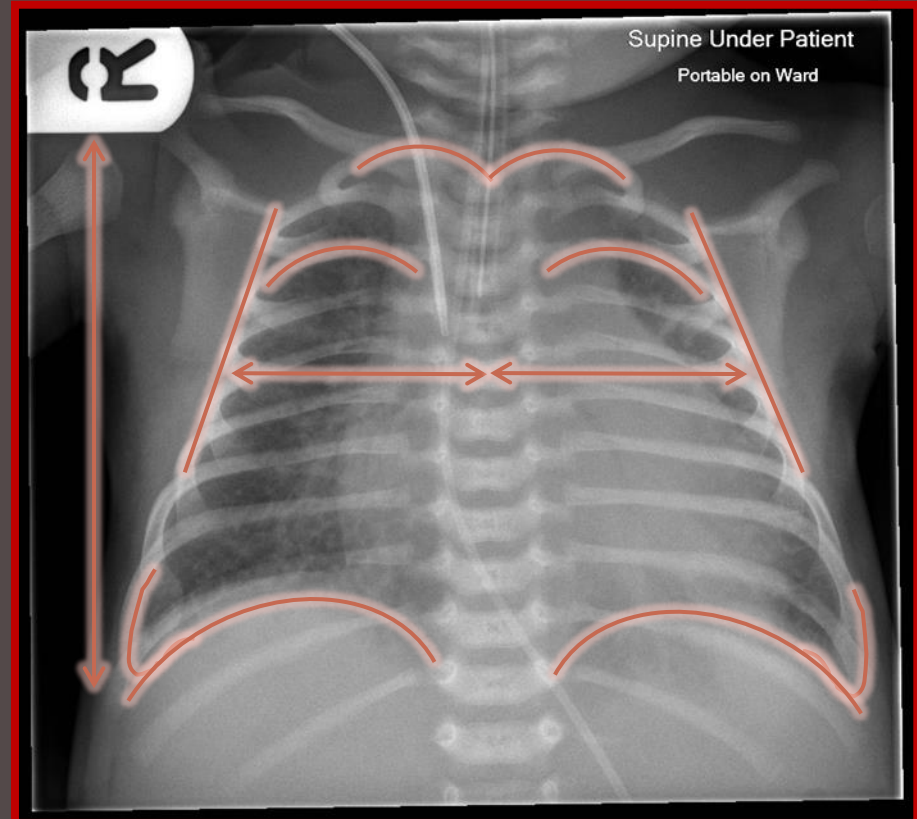
Aim

- Discuss optimal imaging for neonatal chest and abdomen examinations
- Identify obstacles of portable imaging.
- Discuss positioning of Neonates
- Review radiographs throughout

Textbook Chest Imaging

Includes all of the area of interest – Apices to Diaphragm including lateral borders of chest.

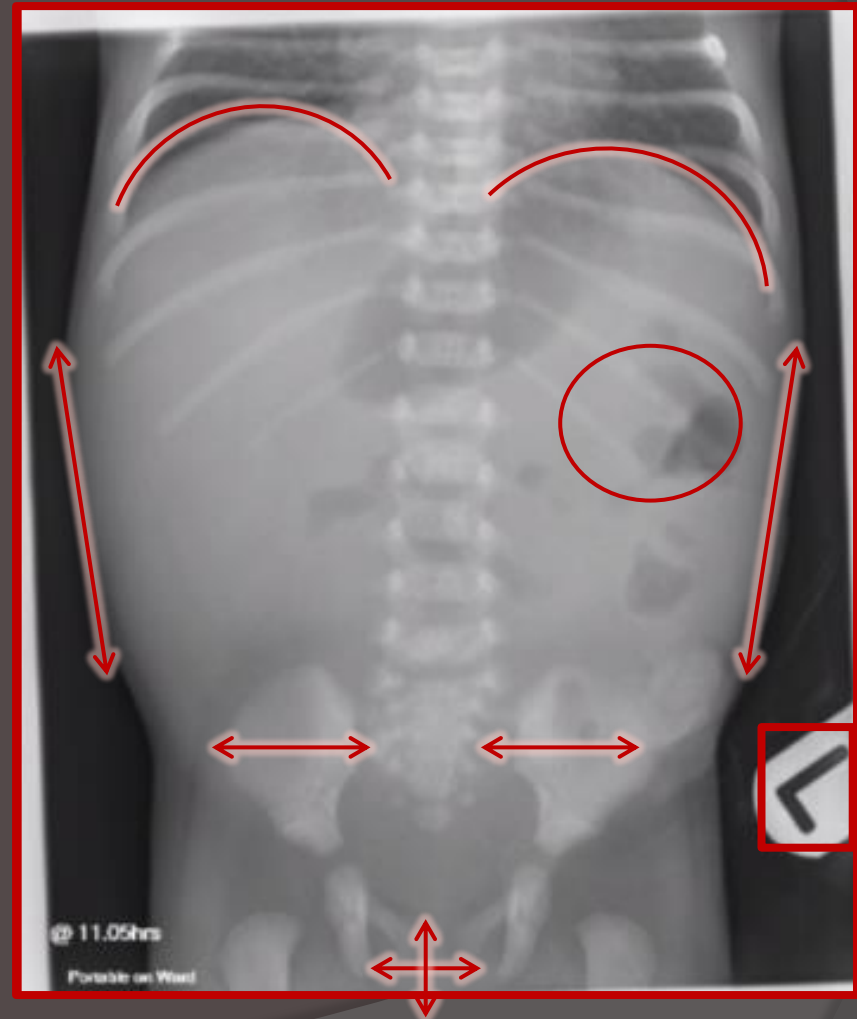
- ✓ Area of interest demonstrated
- ✓ No Rotation
- ✓ No Lordosis
- ✓ Adequate exposure to reproduce the thorax
- ✓ Visually sharp reproduction of thorax
- ✓ Appropriate collimation
- ✓ Physical marker present



Textbook Abdomen Imaging

All area of interest - diaphragm, symphysis pubis including rectum and lateral borders of the abdomen.

- ✓ No rotation
- ✓ No movement un-sharpness
- ✓ Reproduction of soft tissue densities and bowel gas patterned
- ✓ Visually sharp reproduction of bones
- ✓ Appropriate collimation
- ✓ Physical marker present



2 Obstacles identified against achieving 'Textbook Imaging'

Artefacts

Avoidable

Unavoidable

Immobilisation

*Rotation

*Lordosis

*Artefacts

*Movement

*All areas included

*Head position

Identified through departmental audits

Artefacts

Remove/Move all artefacts

○ Chest

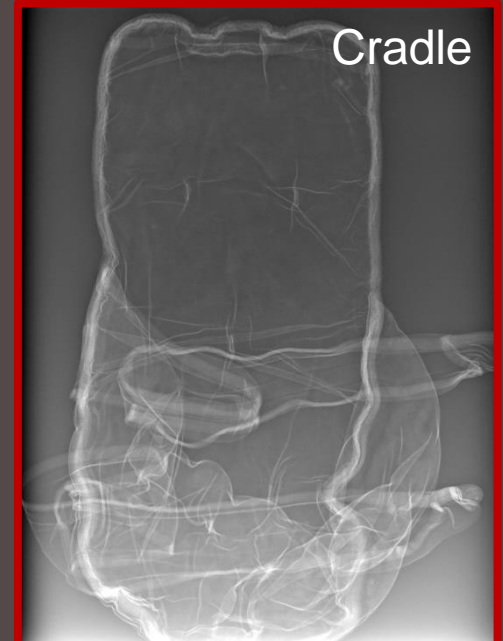
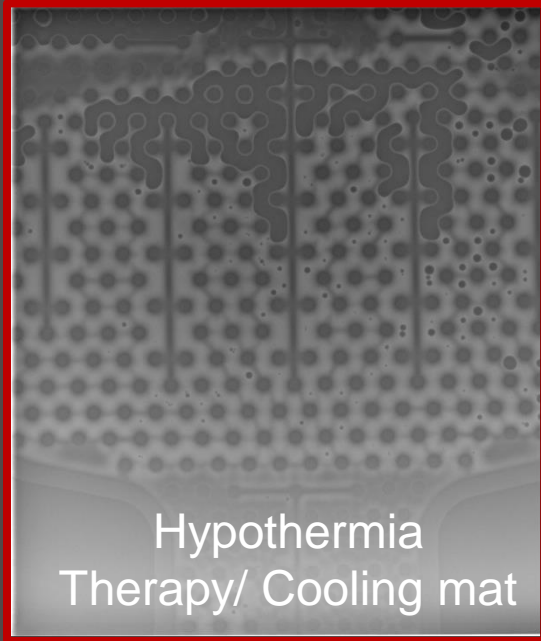
- Clothing
- ECG Leads
- Fingers

○ Abdomen

- Clothing
- ECG leads
- Nappy – First Step to all Abdomen examinations
- Limbs
- Temperature probe

- No cooling mats – if so place detector directly under patient.
- Out of cradles, blankets and any textured fabrics.
- No medical equipment on top of incubators.

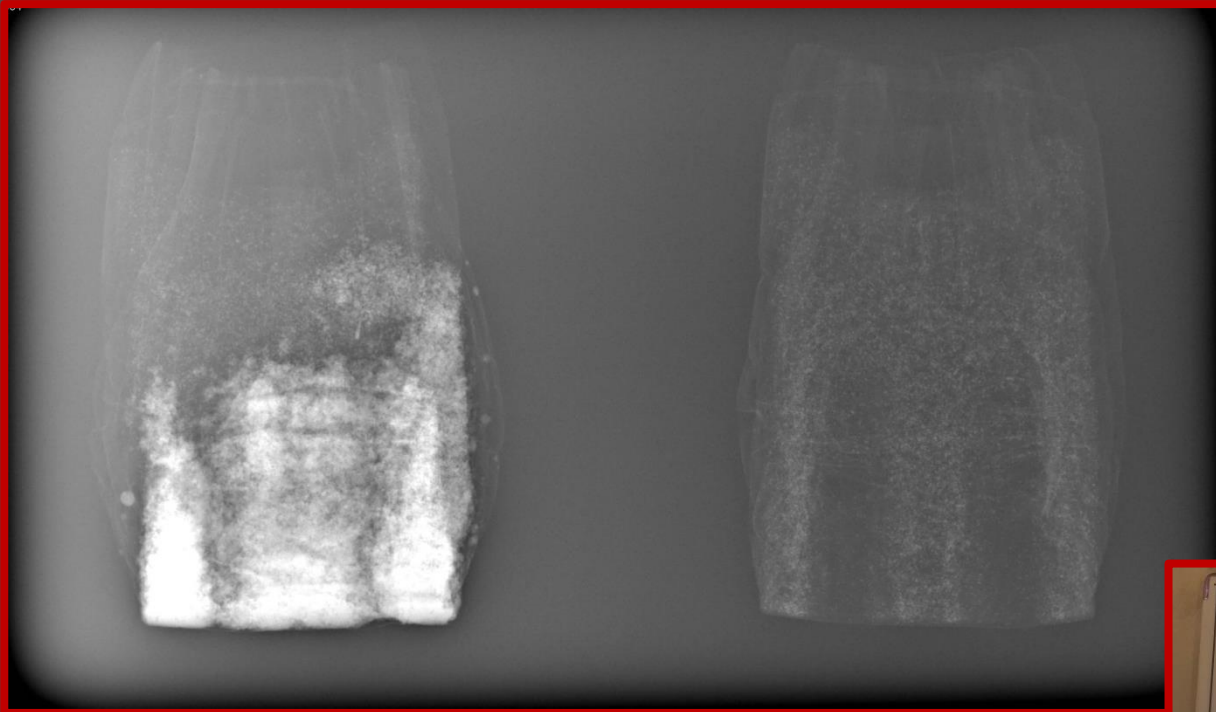
AVOIDABLE ARTEFACTS




Nappy

Wet

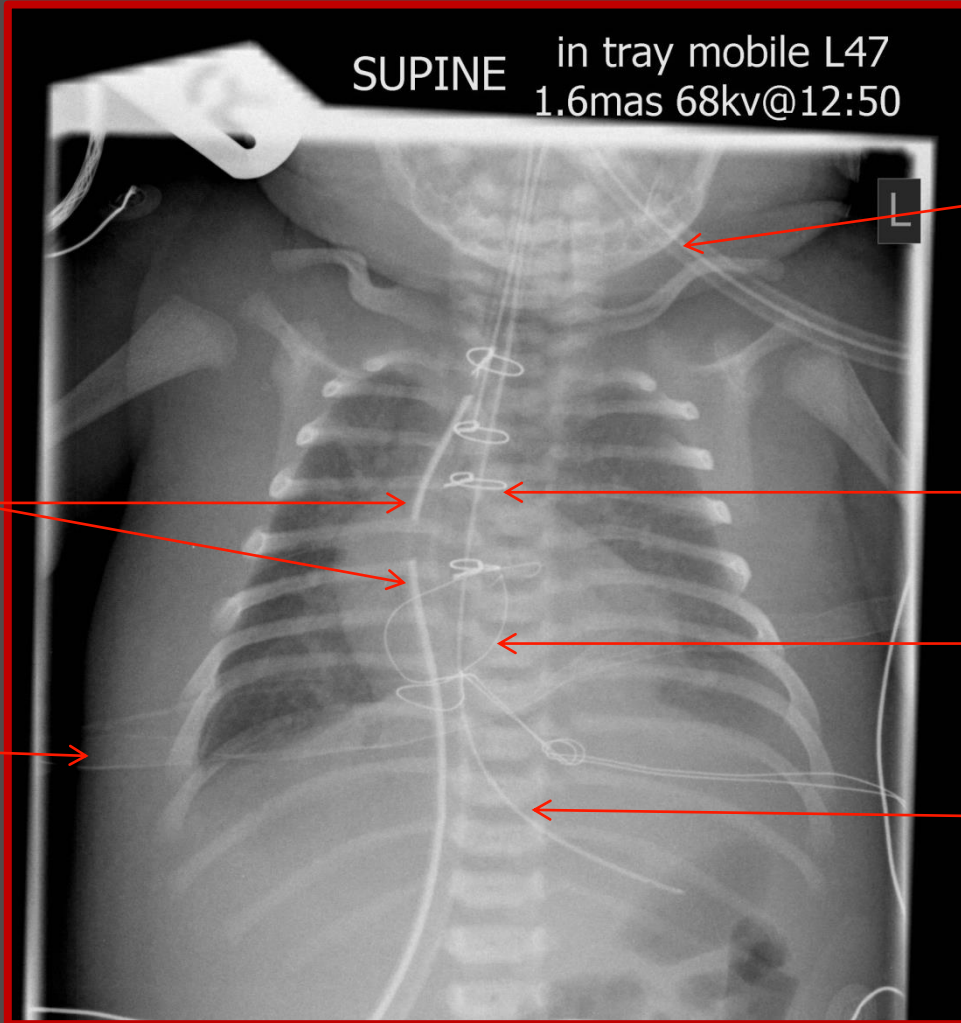
Dry



Regardless of being wet or dry a nappy degrades image quality.



Unavoidable artefacts



ET Tube

Sternal Wires

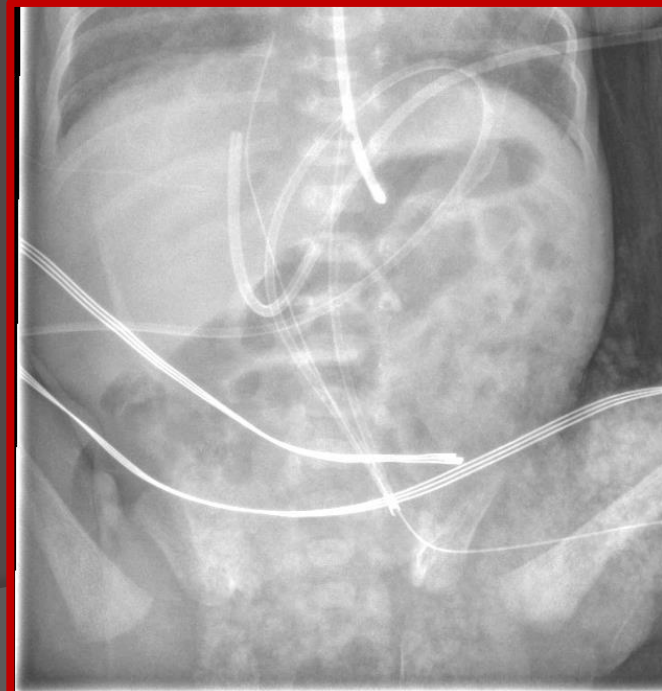
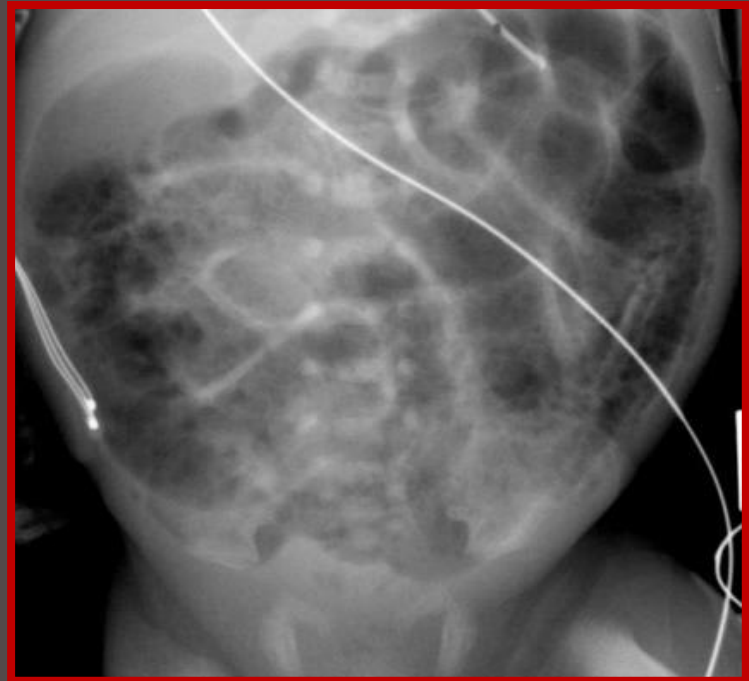
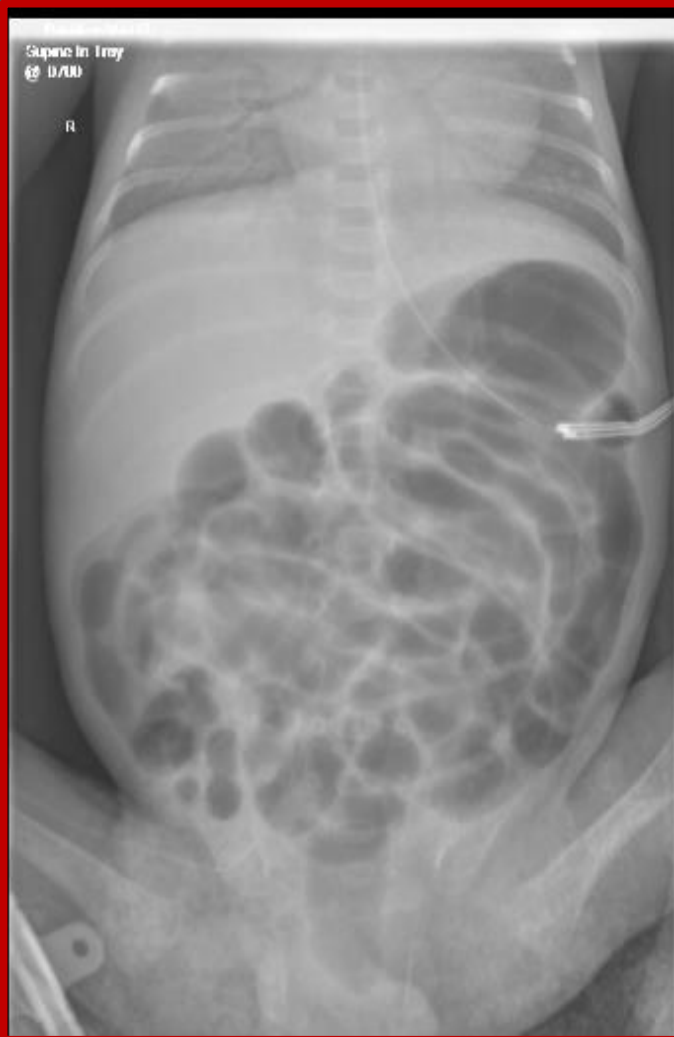Pacing wires

NG Tube

Chest Drain

Mattress

Nappy or NEC



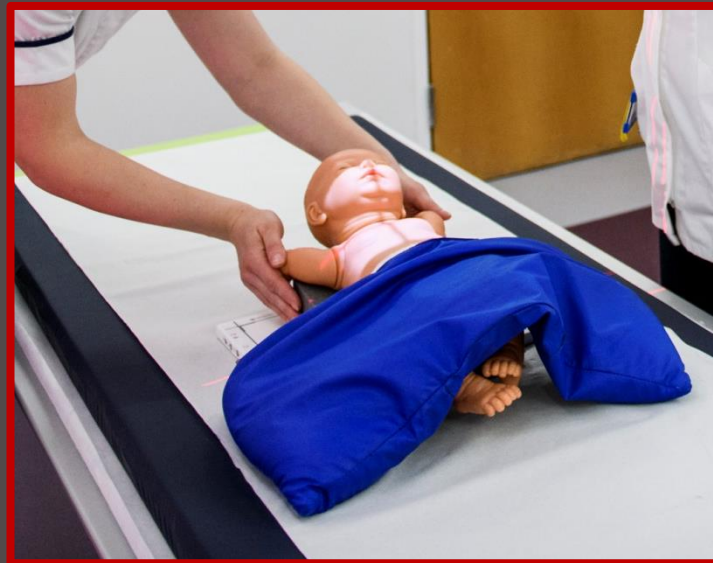Immobilisation

Immobilisation

- *Rotation
- *Lordosis
- *Artefacts
- *Movement
- *All areas included
- *Head position

- No exposure should take place unless the practitioner/operator is certain there has been no movement which would be detrimental to the radiograph.

- Split sandbags
- Blanket rolls across arms
- Blanket across legs



- Can the examination be performed safely with the use of immobilisation techniques and distraction aids?

Immobilisation

- Utilise comforters and carers in accordance with IR(ME)R 17 to:
 - minimise patient distress
 - maintain patient safety
 - assist with patient positioning and immobilisation ensuring optimal image quality is achieved.
 - The carer or comforter's assistance will help minimise the need for repeat exposures keeping radiation dose ALARP.
 - Risk assessments in accordance with IR(ME)R 17 should be in place.
-
- Unable to immobilise using standard techniques?
 - No C&C present?
 - Distressed patient?

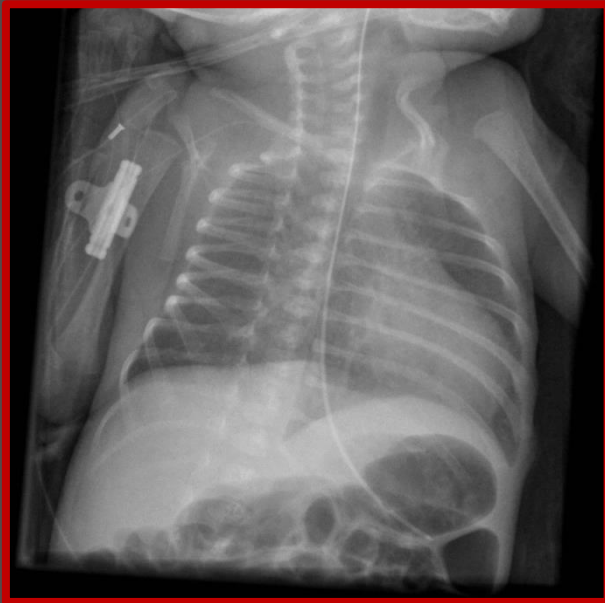
A member of staff may be required to hold the patient in accordance with your departments local rules.

Rotation

Rotation can be extremely detrimental to the diagnostic quality of a radiograph.

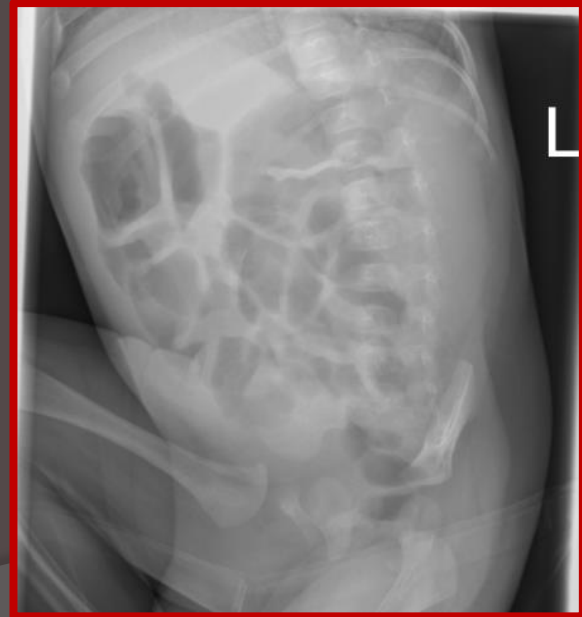○ Chest x-ray

- Heart size
- Lung assessment
- Line Positions



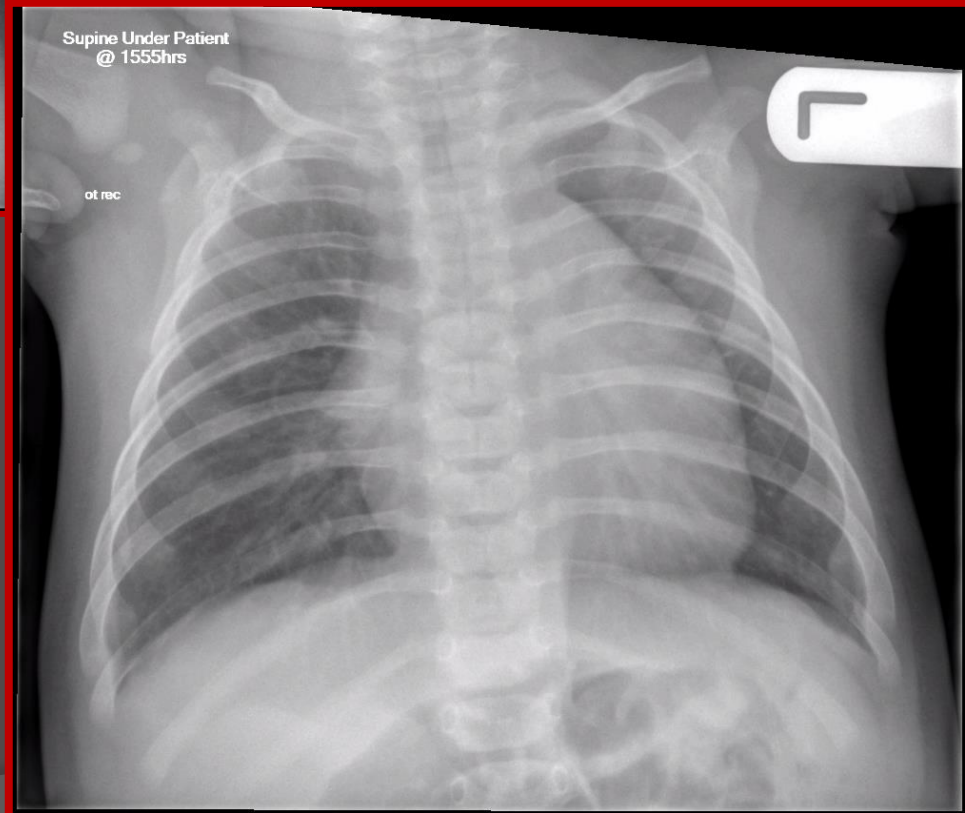
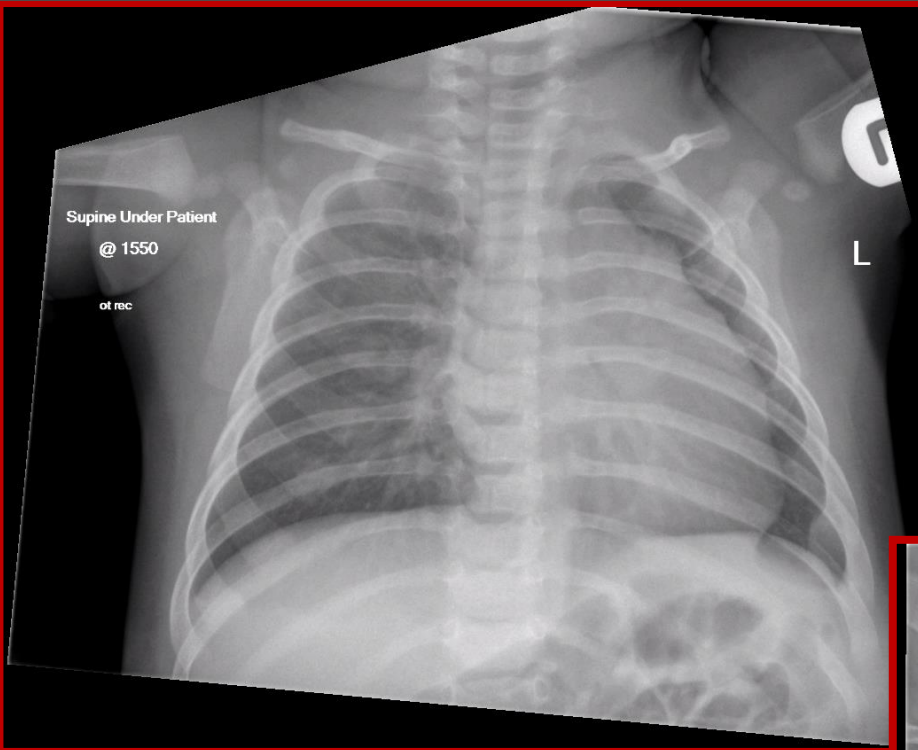
○ Abdomen

- Line positions
- Bowel gas patterns



Subtle Rotation

Original Markers



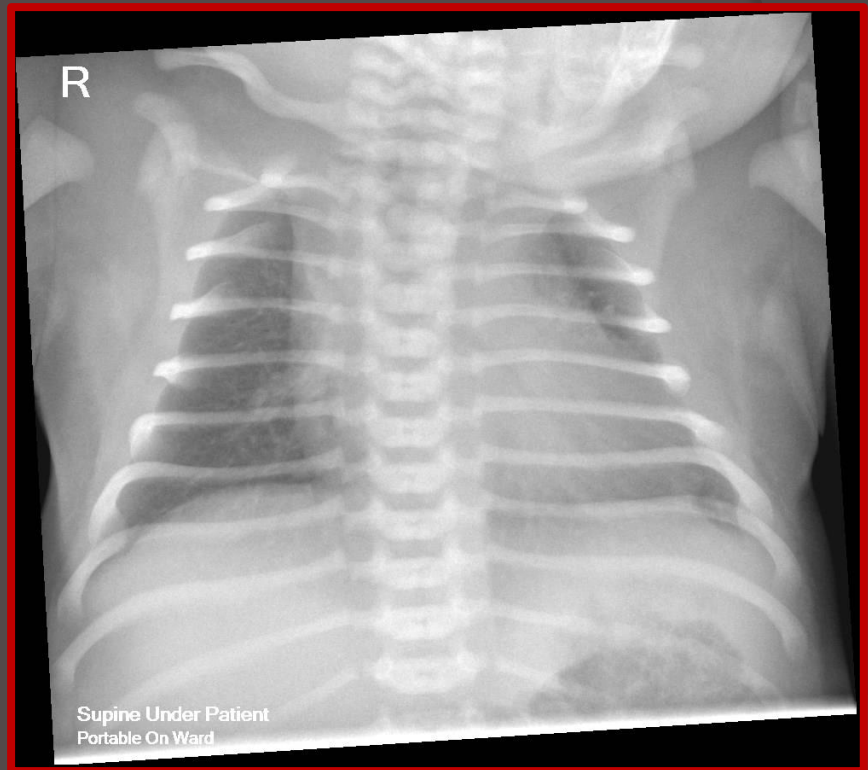
*Heart border distorted due to the minimal rotation.

*Less of the left lung field demonstrated.

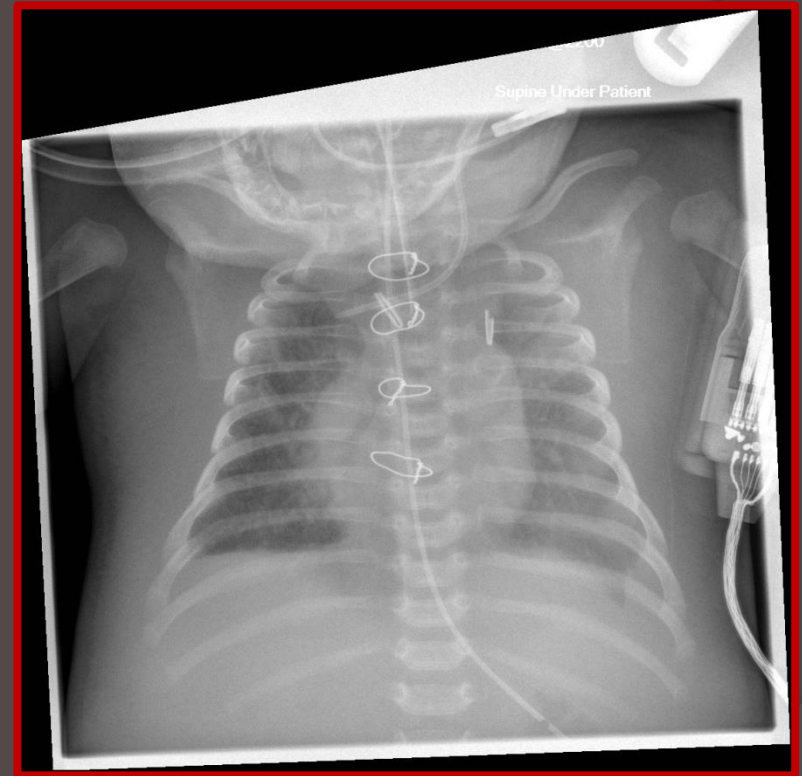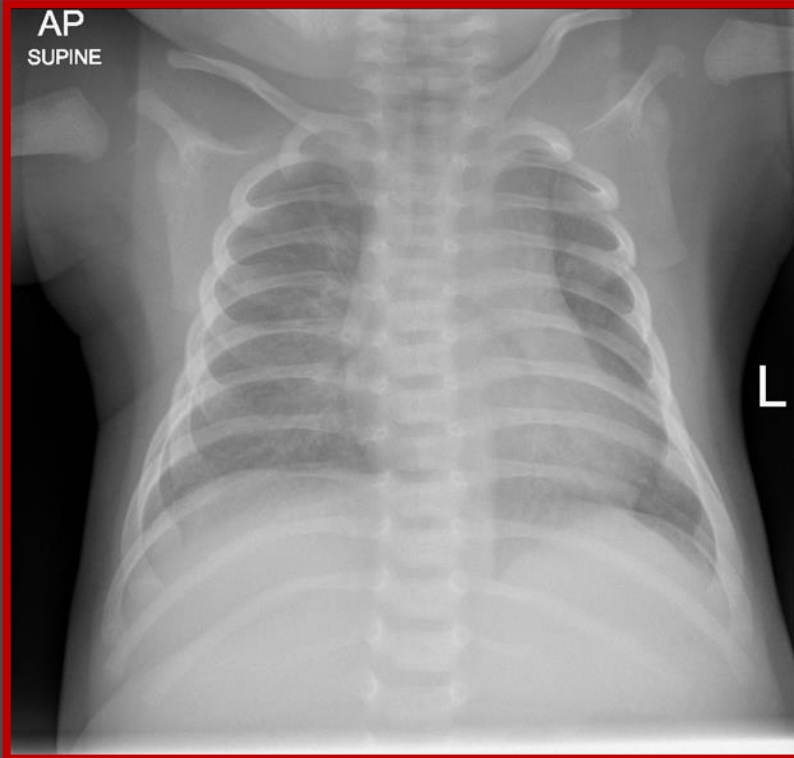
*Blunt left costophrenic angle

Lordosis

- Rotation can emphasise Lordosis.
- Affects the diagnostic quality of radiographs due to the inability to assess Apices, Diaphragm and lung bases.
- Mediastinal distortion.
- Characterised by parallel ribs and blunt bases Diaphragm



Head Position



- The are limitations of patient head position; particularly when intubated. Communicate with the nursing staff and if necessary the referring clinician to see whether head movement is possible.

Area of interest & Collimation

○ Chest

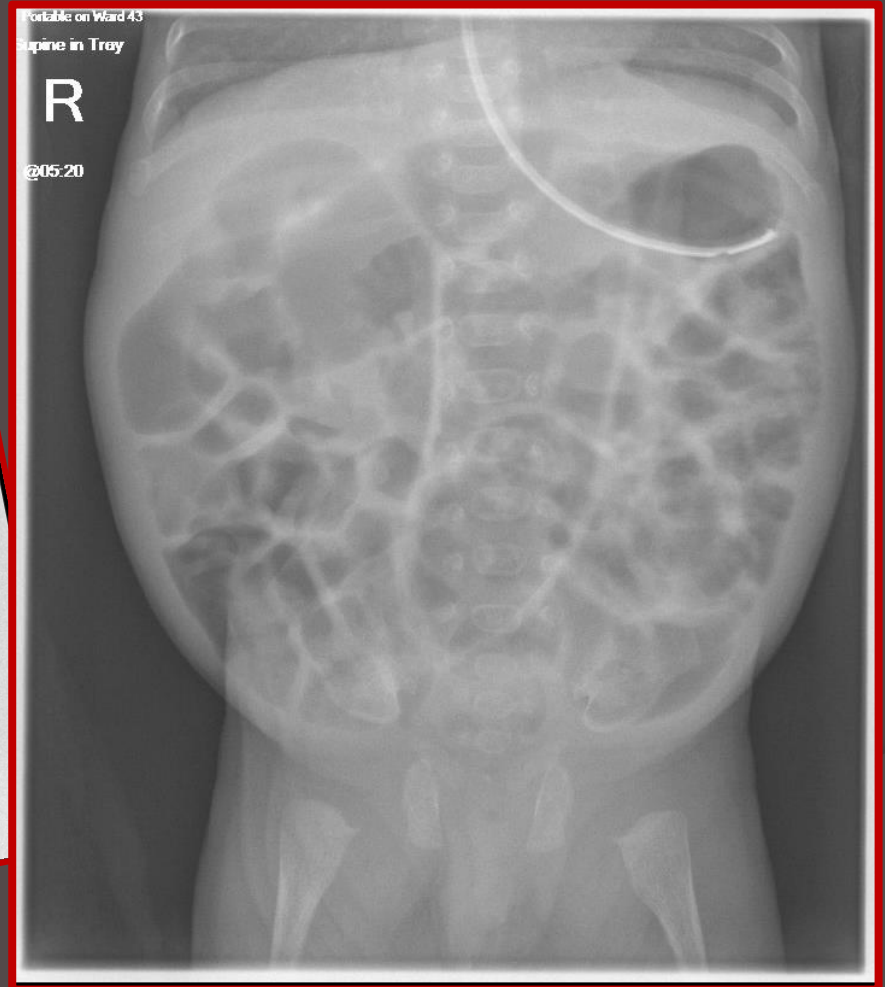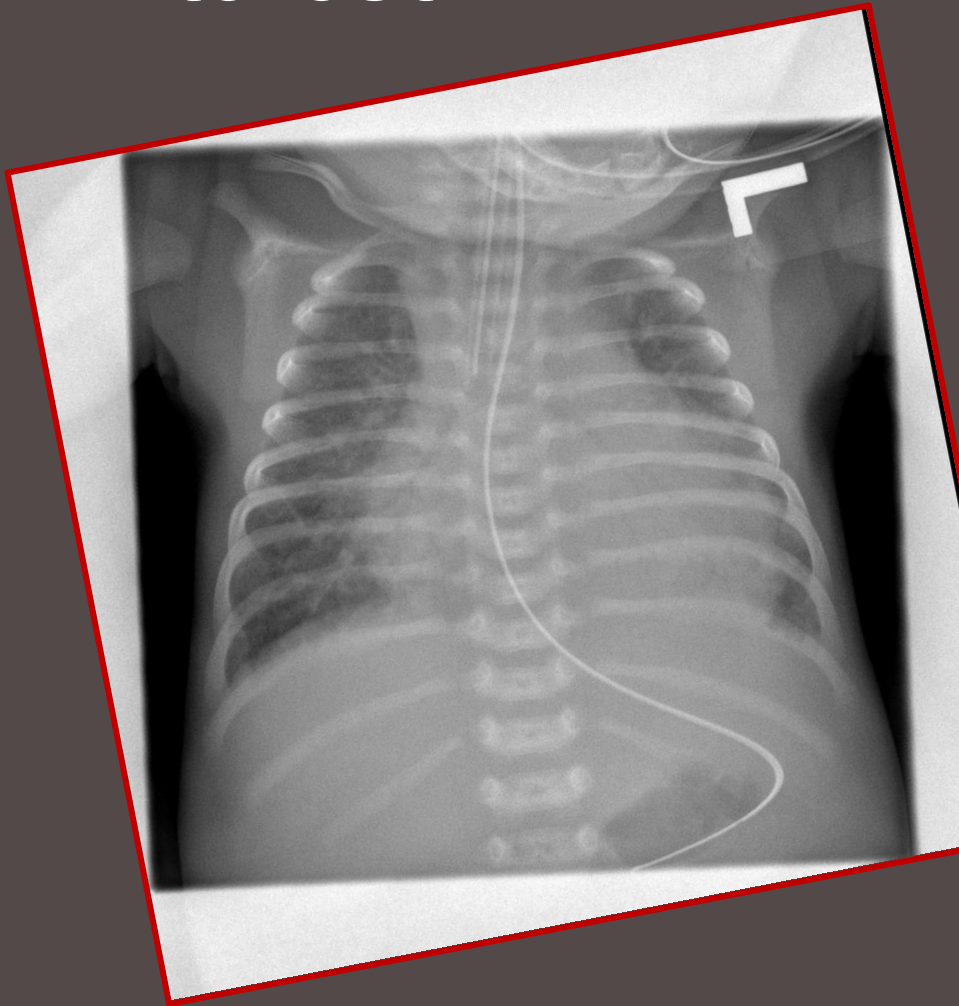
- Apices
- Dia-metaphyseal region of proximal humeri
- L2

○ Abdomen

- Symph
- Lateral margins of the abdomen
- Diaphragm

Failure to immobilise the patient can result in movement which in turn leads to the area of interest being outside the radiographers collimation.

Examples of collimation/ areas of interest



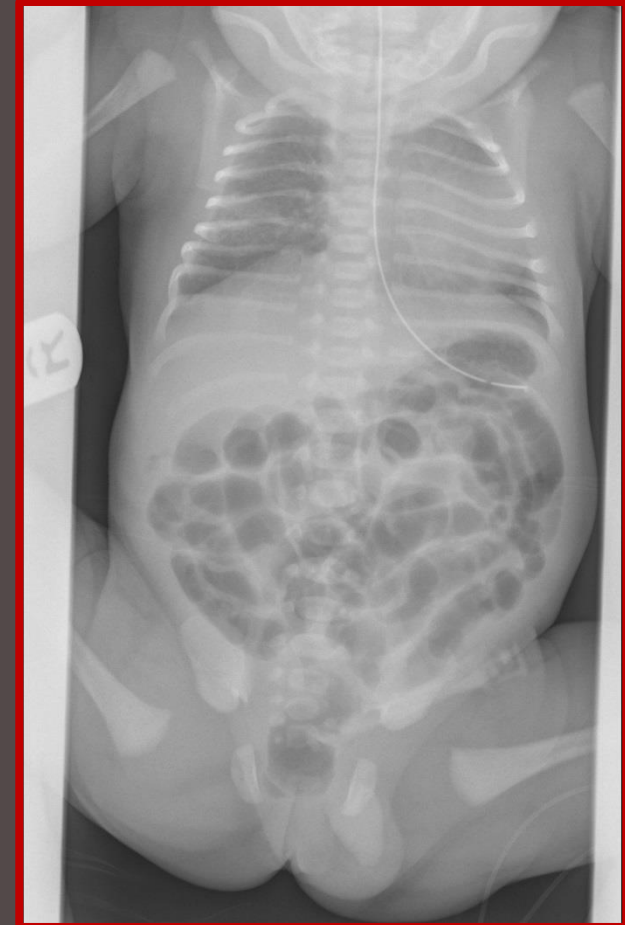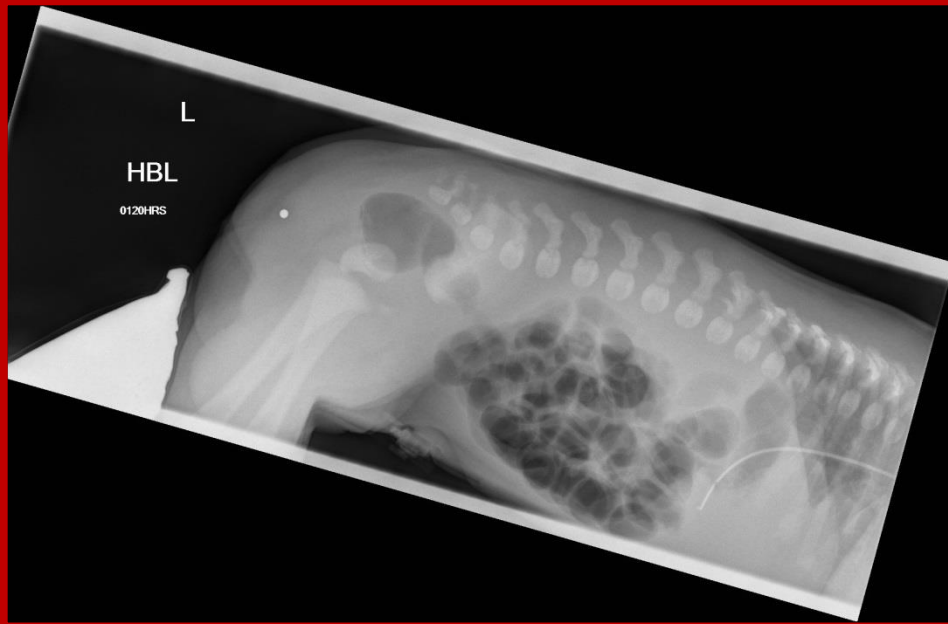
Top Tips

- Angle the incubator slightly or If the child is not intubated and is stable put the patient on a 15 degree sponge pad.
- Checks that the nipples are equidistant from the centre of the patient's body.
- Check the pelvis is not twisted and one crest is not higher than the other.
- Position the patients arms at 90 degrees to the abdomen to prevent radiation exposure to the red bone marrow of the humerii.
- Utilise acceptable immobilisation
 - Split sandbag - Departmental
 - Blankets to swaddle legs to ensure that limbs are not projecting over abdomen.
 - Carers and Comforters - Cupping of arms and legs.
- Communicate with nursing staff.

Additional Views

CXR/AXR

Prone Decubitus



Performed 18 hours after birth to allow gas to pass through the entire digestive tract

Baby must be prone 20mins prior to exposure

Chest & Abdo

Clinical Indication:

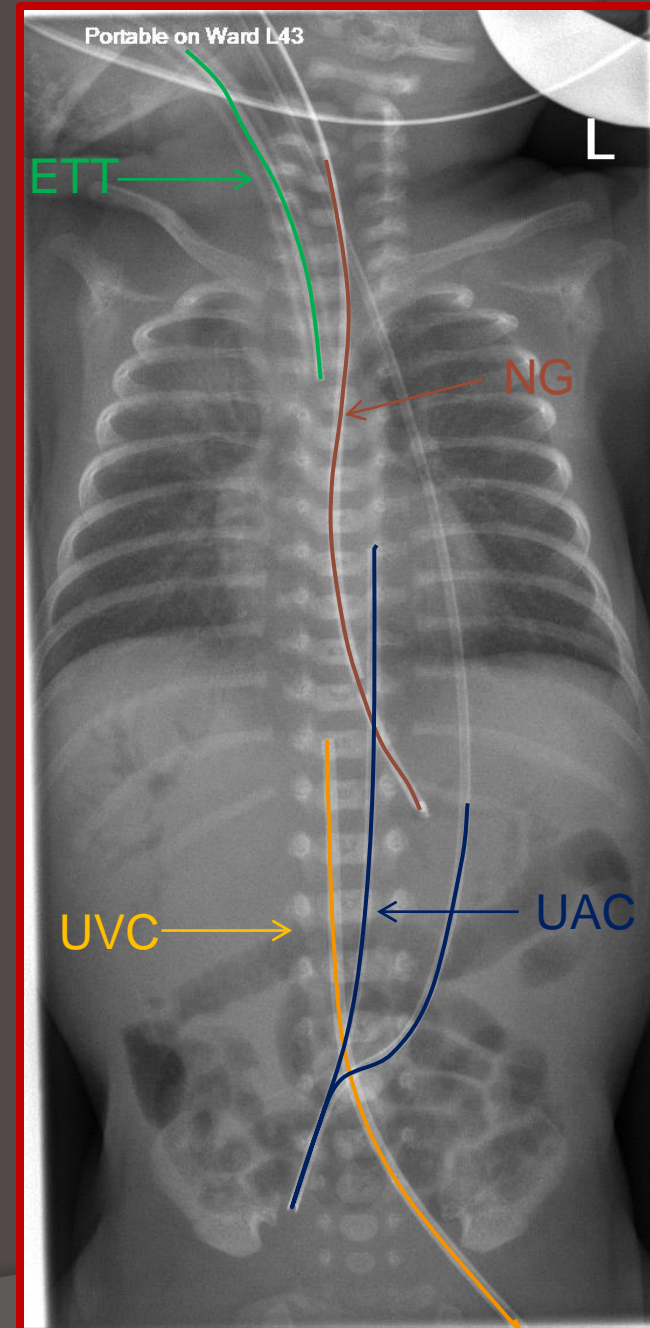
UAC, UVC Line position

UAC - The tip is overlying the vertebral body of T6.

UVC - The tip is overlying the liver.

NGT - The tip should lie below diaphragm

ETT - The tip is 5-10mm above the carina



Conclusion

At the same time as providing a radiograph that answers the clinical question, we should strive to produce a radiograph that can be fully assessed by the Paediatric Radiologists whilst ensuring Radiation dose is ALARP.

Communicate with Paediatric Radiologists and assess department image quality.

Communicate with the nursing teams in particular on Neonates and ICU. Preparation is key.

Thank-you

Any questions?