

PHILIPS

Ultrasound

Clinical case study

The eL18-4 Pure Wave linear array with MicroFlow Imaging (MFI) in diagnosis of thyroid, lymph nodes, and salivary glands in the evaluation of neck pain

eL18-4 PureWave linear array transducer

Category

Thyroid, Head and Neck, and Lymph Node Assessment

Authors

Lynwood W. Hammers, DO
Consultant Radiologist

Hammers Healthcare Imaging, LLC
New Haven, CT

Overview

Diagnostic ultrasound is the standard for the evaluation of neck pain and palpable neck masses. Ultrasound exam is directed by the patient to focal area of pain or the palpable mass.

Patient history

The patient was a 64-year-old female with a palpable left thyroid mass. There had been intermittent pain and swelling in the LL2 area over the submandibular gland. The patient had a course of antibiotic treatment for lymph nodes infection.

Protocol

The thyroid, lymph nodes, and salivary glands were evaluated with the eL18-4 transducer and utilization of MFI vascular assessment. Linear and transverse imaging was performed of the entire neck.

Findings

The eL18-4 transducer more clearly delineates the dilated duct within the submandibular gland. The sharp borders of the duct and serpiginous appearance are especially appreciated. Both transducers identify the large Wharton's duct stone with the eL18-4 characterizing the duct and stone border more sharply.

Conclusion

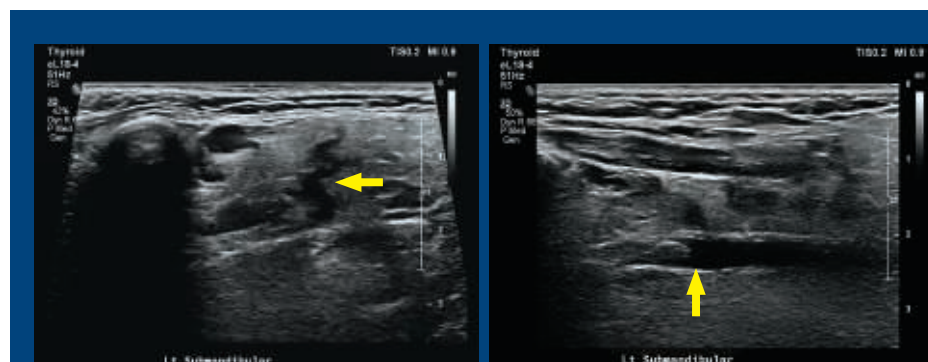
CT scans have primarily been utilized for suspected salivary glands obstruction and the presence of ductal stones. Meticulous scanning with high frequency transducers of the neck can be highly sensitive and accurate. The eL18-4 shows exceptional border definition and therefore provides high confidence in the diagnosis. This allows the surgeon to be more precise in the stone removal at a much greater cost savings.

This case clearly demonstrates the increased sensitivity, and therefore value, of the eL18-4 with MFI in assessment of the salivary glands.



The Philips eL18-4 PureWave linear array transducer is our first high-performance transducer featuring ultra-broadband PureWave crystal technology with multi-row array configuration, allowing for fine-elevation focusing capability.

Results from case studies are not predictive of results in other cases. Results in other cases may vary.



The eL18-4 transducer revealed a prominent duct within the gland.

The eL18-4 transducer identified the large calcification in the dilated Wharton's duct.

The eL18-4 PureWave linear array with MicroFlow Imaging (MFI) in diagnosis of thyroid cancer, lymph node metastasis, and salivary gland abnormalities

Overview

Diagnostic ultrasound is the standard for the evaluation and biopsy of thyroid cancer and metastatic lymph nodes. The diagnosis of salivary gland disease has been enhanced by the utilization of diagnostic ultrasound. Ultrasound is an ideal modality when frequent follow-up exams are required.¹

Patient history

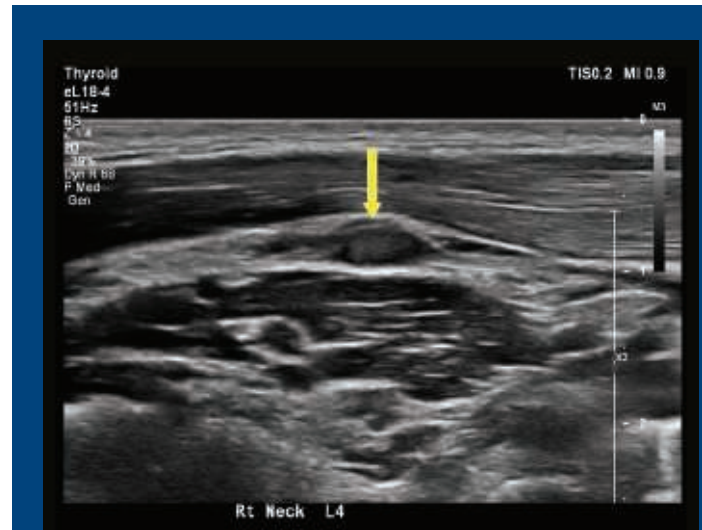
The patient was a 37-year-old female with recent outside biopsy revealing right thyroid cancer. The patient was referred for staging of possible lymph node metastasis prior to surgery. There were no palpable enlarged lymph nodes and no abnormal lymph nodes seen on the outside exam.

Protocol

The patient was scanned with a conventional linear transducer and eL18-4 transducer from the angle of the mandible through the supraclavicular region, which included L1 – L6. Lymph node evaluation for calcium or fluid presence was noted. All size lymph nodes were evaluated without negation for small size.

Findings

Although the lymph node was small, the eL18-4 transducer revealed a small area of fluid at the edge of the lymph node. The lymph node was biopsied and was positive for metastatic thyroid cancer.



The eL18-4 transducer revealed a 4 mm right L4 heterogeneous lymph node without calcification. There was loss of the normal echogenic center.

Conclusion

Evaluation of lymph nodes in the central and lateral neck both pre- and post-op is important for staging and planning surgical intervention. Enlarged lymph nodes do not indicate metastasis, nor do small lymph nodes indicate benign disease. Lymph node with loss of the normal echogenic center does not mean cancer, as most are benign. The presence of calcification or fluid raises suspicion and should suggest biopsy, even in a 4 mm lymph node.

The enhanced image quality of the eL18-4 transducer led to the biopsy of the right L4 lymph node, which was positive for cancer. This finding led the surgeon to perform a modified radical surgery on the right, and additional small lymph nodes were found to be positive.

The initial surgery was performed with less chance of recurrence because of the high-quality imaging of the eL18-4 transducer.

Reference

1 Tessler FN, MD, CM; Hammers LW, DO; et al. ACR Thyroid Imaging, Reporting and Data System (TI-RADS): White Paper of the ACR TI-RADS Committee. JACR 2017.

Results from case studies are not predictive of results in other cases. Results in other cases may vary.