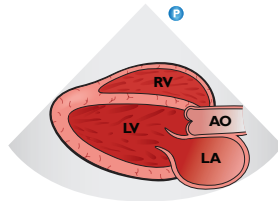
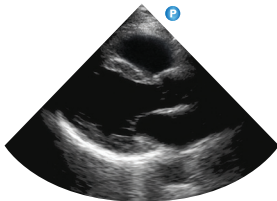
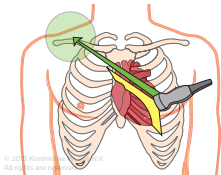


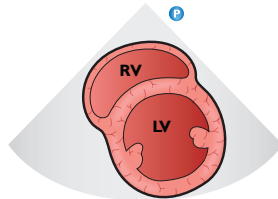
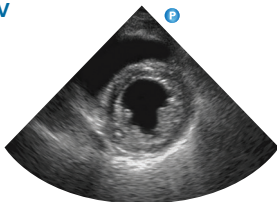
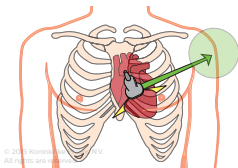
Introduction to transthoracic echo – POC views

Philips Healthcare

Parasternal long-axis

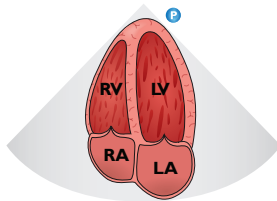
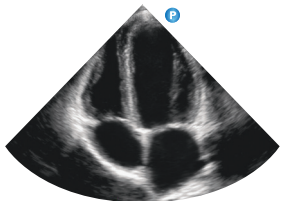
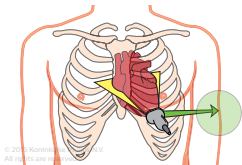


Parasternal short-axis LV

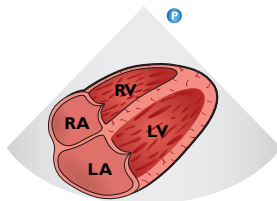
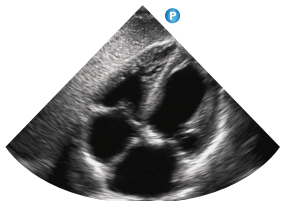
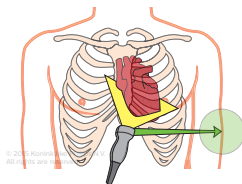


PHILIPS

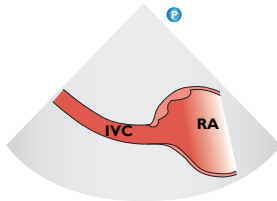
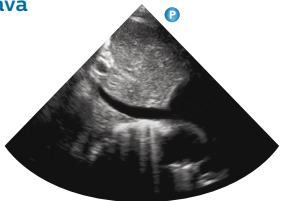
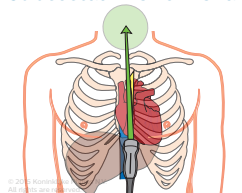
Apical four-chamber



Subcostal four-chamber



Subcostal inferior vena cava



To view the complete
“Introduction to
transthoracic echo”
tutorial visit:

www.philips.com/Sparq
or www.philips.com/CCEMeducation

or download the Philips
Ultrasound Education
iPad App from the
App Store (search using
Philips ultrasound).



Philips Healthcare reserves the right to
make changes in specifications and/or
to discontinue any product at any time
without notice or obligation and will not
be liable for any consequences resulting
from the use of this publication.

© 2015 Koninklijke Philips N.V.
All rights are reserved.
MAR 2015